

Sonographic evaluation of abdominal organs in sickle cell disease patients

Kaushal L¹, Verma VK², Ahirwar CP³, Patil A⁴, Singh SP⁵

¹Dr Lovely Kaushal, Associate Professor & Head, Department of Radiodiagnosis, GMC, Bhopal, ²Dr V K Verma, Associate Professor, Department of Radiodiagnosis, GMC, Bhopal, ³Dr C.P.Ahirwar MD, Asst. Professor, Department of Radiodiagnosis, GMC, Bhopal, ⁴Dr A Patil MD, Asst. Professor, Department of Radiodiagnosis, GMC, Bhopal, ⁵Dr Shakti Pratap Singh, Resident, Department of Radiodiagnosis, GMC, Bhopal, MP, India

Address for correspondence: Dr Lovely Kaushal, Email: drlovelykaushal@gmail.com

Abstract

Background: SCD is one of the most common inherited hemoglobinopathies worldwide. It is a major health problem in Madhya Pradesh and surrounding states. The present study was undertaken to infer the value of ultrasonography in evaluating abdominal organs in a SCD patient. **Study design:** This is a prospective hospital based study. **Method:** 100 SCD patients were assessed for abdominal pathologies by USG, the results thus analyzed and prevalence was calculated. **Result:** Hepatomegaly is the most common association observed in 69% of patients followed by splenomegaly in 31% patients & increased renal size in 29% patients. Cholelithiasis (17%), increased renal medullary echogenicity (14%), Auto-splenectomy (11%), Bright liver (9%), Splenic calcification (8%), Increased GB wall thickness (6%), Splenic infarct (5%) and Increased pancreatic echogenicity (3%) are the other associated findings. **Conclusion:** Real time ultrasonography is a simple, cheap, rapid, easily accessible, non-invasive, non-ionizing screening procedure in all cases of SCD patient for assessment of pathological changes occurring in the various abdominal organs. The high rates of abdominal pathologies being diagnosed on ultrasonography underscores the need for it to be established as a standard screening procedure with established protocols.

Key Words: Sickle cell disease (SCD), Ultrasonography, Hemoglobinopathies

Introduction

Sickle cell disease (SCD) is among the most common of inherited hemoglobinopathies. The disease has been known since James Herrick, a Chicago cardiologist, in 1910 first reported it as “peculiar elongated and sickle-shaped red corpuscles in a case of severe anemia” [1].

The term sickle cell disease (SCD) is a group of inherited disorders characterized by defective hemoglobin (Hb) synthesis.

A single mutation leads to replacement of Glutamic acid with Valine in position 6 of the β globin chain resulting in a mutant form of Hb known as Sickle Hb (HbS) [2, 3]. In certain states like Madhya Pradesh, Orissa, Chhattisgarh, Jharkhand, Gujrat and Maharashtra it forms a major public health problem [4].

Sickle cell disease, particularly in homozygous state, has a significant contribution to the morbidity and mortality of this disorder during crisis. The various types of crisis cause changes in different organs of the body, some of which may have long term complications to the sickle cell

patient. Most of these changes occur in the abdominal organs, that is the liver, kidneys, spleen, gall bladder, as well as the pancreas. Early detection of these changes enables the caretakers to take preventive measures. Real time Ultrasonography is the most simple, cheap, easily accessible, non-invasive & non-ionizing modality playing an important role in detecting early pathological changes so that appropriate interventional measures can be carried out.

Real time ultrasonography is now becoming standard screening procedure in all cases of SCD patients for assessment of pathological changes occurring in the abdominal organs, especially liver, biliary tract, spleen, kidneys and pancreas. The extent & changes in the various organs can be accurately observed by US and there by helps the clinicians to modulate their treatment.

In all cases of acute SCD crisis, On the basis of Ultrasonographic findings they can be divided, whether they need surgical or medical intervention. This study is about the sonographic evaluation of abdominal organs in sickle cell disease. The Present study is a Prospective study conducted in GMC & HH Bhopal, in Madhya Pradesh, India. We have conducted this study to determine the prevalence and distribution of abnormal

Manuscript received: 22nd Jan 2014
Reviewed: 15th Feb 2014
Author Corrected: 23rd Mar 2014
Accepted for Publication: 30th Mar 2014

Ultrasonographic findings in the liver, biliary tracts, Spleen, kidneys And Pancreas of patients with SCD.

Material & Methods

Study Design:- Prospective hospital based study.

Study Area:- Gandhi Medical College & Hamidia Hospital Bhopal.

Sample Source:- SCD patients from all the departments of GMC & HH referred to department of Radiodiagnosis for Ultrasonography of abdomen.

Sample Size:- 100 patients

Inclusion Criteria:- All the cases taken for study were sickling positive.

Exclusion criteria:- Negative sickling test, Positive operative history of splenectomy or others.

Technique of Scanning:- The Scan should be started with a convex probe of 3.5MHz used for visualization of solid organs, and linear array probe 7-10 MHz used for visualization of bowel and superficial tissues.

Definition of Terms

Hepatomegaly: For adults patient's hepatomegaly was

taken as length greater than 15.5cm in long axis [5]. however other criteria for hepatomegaly are preaortic >10cm and prerenal>14cm. The organ size was compared to the Indian reference population obtained from a study published on Indian population [6].

Bright liver: A normal liver is more echogenic than the renal cortex and less echogenic than the spleen [5].

Splenomegaly: For adult patients, splenomegaly was taken as length greater than 13.0cm in long axis [5]. The organ sizes was compared to the Indian reference population obtained from a study published on Indian population [6].

Renal enlargement: Upper limits of normal right and left kidney were taken as 12.8mm & 13mm respectively for adults [7].

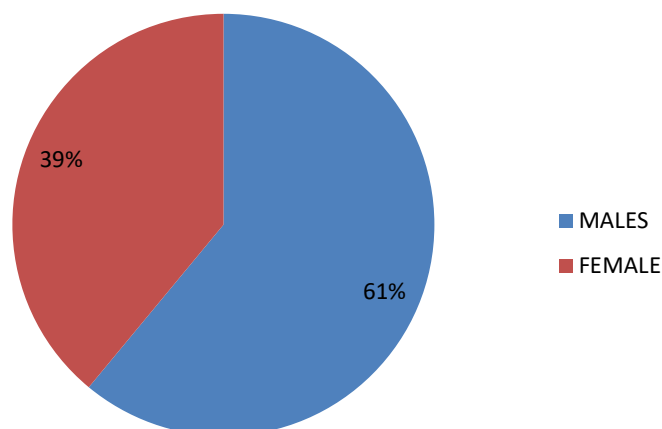
Increased renal echogenicity: Normal renal echogenicity is typically less than adjacent liver and spleen [5].

Thickened GB wall: A thickened gall bladder wall measures >3mm and typically has a layered appearance on ultrasonography [8].

Increase pancreatic echogenicity: The normal pancreas has been stated to have echogenicity equal to or just greater than that on gray-scale images.

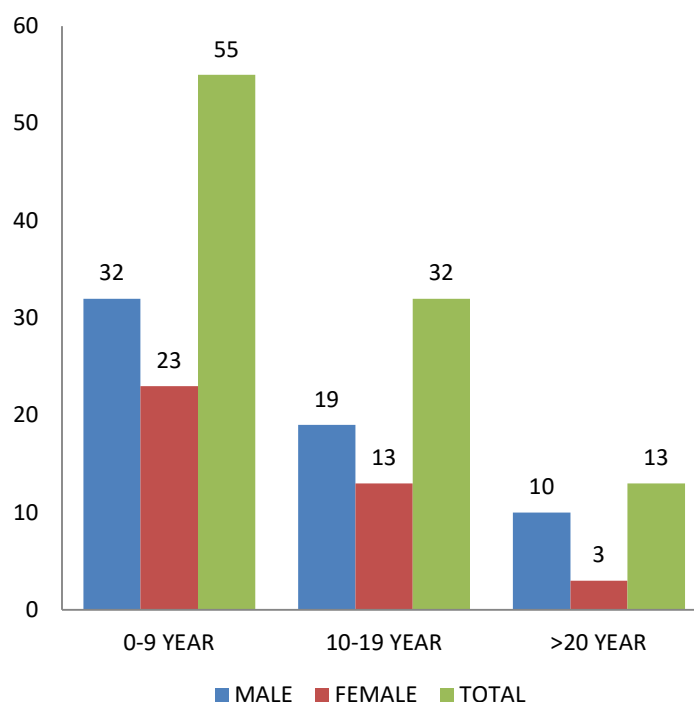
Results

Figure 1: Distribution of sample population by sex



This study comprises of 100 patients out of which 61 (61%) were males and 39 (39%) were females. Males were more common in our study comprising 61% followed by 39%female.

Figure 2: Distribution of patients in age groups



Showing subjects distribution in various age groups. The age groups 0-9 years consisting of 55 (55%) patients out of which 32 (58.2%) are males and 23(41.8%) are females. 10- 19 years consisting of 32(32%) patients out of which 19(59.4%) are males and 13 (40.6%) are females. Least number of patients were of > 20year age group being 13 out of which 10 (76.9%) are males and 3 (23.1%) are females.

Table 1: Distributions of ultrasonographic findings in liver by age

Ultrasonographic Findings	Age Years			Total
	0-9	10-19	20+	
Normal Liver	14(25.4%)	10(31.25%)	3(23.1%)	27
Hepatomegaly	43(78.1%)	17(53.1%)	9(69.2%)	69
Bright Liver	1(1.8%)	6(18.8%)	2(15.4%)	9
Total	55(55%)	32(32%)	13(13%)	100

Hepatomegaly is found to be the most consistent finding with an overall prevalence of 69% and prevalence of 68.8% in males and 69.2 % in females. It is most commonly seen in 0-9 years (78.1%) of age. The prevalence of bright liver is 11.5% in males and 5.1% in females with a much higher prevalence in age group of 10-19 years (18.8%).

Table 2: Distribution of Ultrasonographic Findings in Gall Bladder by Age

Ultrasonographic Findings	Age Years			Total
	0-9	10-19	20+	
Normal Gall Bladder	50 (90.9%)	28 (87.5%)	5 (38.5%)	83
Increased Wall Thickness	2(3.6%)	1(3.1%)	3(23.1%)	6
Cholelithiasis	7(12.7%)	3(9.4%)	7(53.8%)	17
Total	55	32	13	100

An overall prevalence rate of 17% was noted in the cases of cholelithiasis with prevalence of 16.4% in males and 17.9 % in females. Prevalence of Increased Gall bladder wall thickness was noted as 6% and the prevalence being 3.3% in males and 10.2% in females. The overall prevalence of increased Gall bladder wall thickness and cholelithiasis was found to increase with an increase in age and had a slight female preponderance.

Table 3: Distribution of Ultrasonographic Findings in Spleen by Age

Ultrasonographic Findings	Age Years			Total
	0-9	10-19	20+	
Normal Spleen	34(73.9%)	10(21.7%)	2(4.3%)	46
Splenomegaly	19(34.5%)	8(25%)	4(30.8%)	31
Splenic Infarct	0(0%)	4(12.5%)	1(7.7%)	5
Splenic Calcifications	2(3.6%)	6(18.8%)	0(0%)	8
Autosplenectomy	0(0%)	6(18.8%)	5(38.5%)	11
Total	55(55%)	32(32%)	13(13%)	100

Splenomegaly is the second most common finding with an overall prevalence of 31%, the prevalence being 29.5% in males and 33.3% in females. It was observed that the prevalence of splenomegaly is higher in 0-9 year age group. The other significant finding in spleen is Auto-splenectomy with an overall prevalence of 11%. An increase in prevalence of auto-splenectomy with age is noticed in the study with a slight male preponderance. The overall prevalence of splenic infarct and splenic calcification is 5% and 8% respectively. However, the prevalence of splenic infarct and calcification was higher in the age group of 10-19 years. A slight female preponderance is noted in cases of splenomegaly and calcification.

Table 4 Distribution of Ultrasonographic Findings in Spleen by Sex

Ultrasonographic Findings	Sex		Total
	Male	Female	
Normal Spleen	24(39.3%)	22(56.4%)	46
Splenomegaly	18(29.5%)	13(33.3%)	31
Splenic Infarct	3(4.9%)	2(5.1%)	5
Splenic Calcifications	4(6.5%)	4(10.2%)	8
Autosplenectomy	8(13.1%)	3(7.7%)	11
Total	61(61%)	39(39%)	100

The prevalence of splenomegaly & splenic calcification is slightly higher in female; however the prevalence of splenic infarct has no sex preponderance. The prevalence of auto-splenectomy is slightly higher in male patients.

Table 5 Distribution of Ultrasonographic Findings in Kidneys by Age

Ultrasonographic Findings	Age Years			Total
	0-9	10-19	20+	
Normal Kidneys	37(67.2%)	23(71.8%)	8(61.5%)	68
Increase Size	20(36.4%)	7(21.9%)	2(15.4%)	29
Increased Medullary Echogenicity	5(9.1%)	6(18.7%)	3(23.1%)	14
Total	55	32	13	100

The 3rd most common finding noted in the study was increased renal size with an overall prevalence of 29% and the prevalence being 29.5% in males and 28.2% in females. It was observed that prevalence is higher in age group of 0-9 years. The increased medullary echogenicity was noted in 14% of patients with a prevalence of 13.1 % in males and 15.4 % in female with a maximum prevalence in >20 years age group demarcating an increase in prevalence with age. However, the presence of confounding factors cannot be excluded.

Table 6: Distribution of Ultrasonographic Findings in Pancreas by Age

Ultrasonographic Findings	Age Years			TOTAL
	0-9	10-19	20+	
Normal Pancreas	53(96.4%)	32(100%)	12(92.3%)	97
Increased Echogenicity	2(3.6%)	0(0%)	1(7.7%)	3
Total	55	32	13	100

Increased echogenicity of pancreas (viz a viz echogenic pancreas) is having a prevalence of 6%. It was observed that the echogenicity of pancreas increases with age, however no sex preponderance was observed.

Cholodocholithiasis with dilated CBD was observed in 1 patient out of the study group of 100 patients. However, a significant correlation with disease in question could not be established. The finding may be considered as a rare complication.

Discussion

The Present study is a prospective study conducted in GMC & HH Bhopal, from June 2012 to December 2013 in Madhya Pradesh, India for Ultrasonographic evaluation of abdominal organs in sickle cell disease done on SCD patients referred for ultrasonography from various Department of Gandhi Medical College & Hamidia Hospital.

Liver

Vascular occlusion, viral hepatitis, iron overload, and drug reactions mainly contribute to SCD related Liver diseases. In our study Hepatomegaly is the most common pathological finding, its prevalence being 69%. This concurs with the study done by Papadaki et al in 2003[9] cited before whereby the prevalence of hepatomegaly was 70.5%.

This is also in accordance with the study done by Ali balci et al in 2004 [10], Mohanty et al [11] in 2004, whereby the prevalence of hepatomegaly was 71.6% & 72% respectively. However this frequency is slightly lower compared to studies done by Bakhieta Ibrahim et al in 2010 [12] & Sadishu et al [13] in 2012 whereby the prevalence of hepatomegaly was 87.8% & 98.6% respectively, and much higher than the study done by Hamim et al in 2012 where it was 28.3%.[14]

Several features of liver histology in patients with SCD may contribute to bright liver including hemosiderin pigment deposition, periportal fibrosis, and distension of sinusoids with sickle cells. In our study prevalence of Bright Liver (Increased liver echogenicity) was found to be 9%. This concurs with the study given by Hamim et al in 2012 whereby the prevalence of bright liver was 12.5%. However this frequency is slightly higher than the

study did by Papadaki et al in 2003 [9] & Ali Balci et al in 2004 [10] in which the prevalence of bright liver was 3.8% & 5.9% respectively.

Spleen

The spleen possesses a slow, tortuous microcirculation that renders it quite susceptible to congestion, sludging, and polymerization culminating into pathologies like splenomegaly, splenic infarct, splenic calcification & auto-splenectomy [15].

In our study, the prevalence of splenomegaly was found to be 31%. This is slightly higher than the studies done by Ma'aji et al in 2012 [16] where the prevalence of splenomegaly was 22.4% & 21.2% respectively. However the prevalence of splenomegaly in studies given by Ahmed H et al in 1997 [17] & Babadoko et al in 2011 [18] was 11.8% & 4.05% respectively.

The repeated sickling of red cells in the splenic circulation over time leads to splenic infarction. In our study the prevalence of splenic infarct was found to be 5%. It concurs with the study given by Hamim A et al in 2010 [14] where the prevalence of splenic infarct was observed as 6.6%. However, this is quite below the study given by Mohanty et al in 2004 [14] where the prevalence of splenic infarct was found to be 22%.

In our study the prevalence of splenic calcification is 8%. This concurs with the study given by Mohanty et al in 2004 [14] where the prevalence of splenic calcification was found to be 10%.

In our study the prevalence of autosplenectomy is observed as 11%. This frequency is slightly higher than

the study done by Ahmed H Salem et al in 1997 [17], Hamim A et al in 2010 [14] & Ma'aji et al in 2012 [16] where the prevalence of autosplenectomy was observed as 6.6%, 6.6% & 4.2% respectively. However, the prevalence of auto-splenectomy was much higher in study given by Ali Balci et al in 2004 [10], Bakhietta et al in 2010 [12] & Babadoko et al in 2011 [18] whereby the prevalence of auto-splenectomy was 33.3%, 47.8% & 55.4% respectively.

Gall bladder

Gallstones are a common complication in patients with SCD owing to stasis, chronic hemolysis and repeated blood transfusions [14]. In our study the prevalence of Gall Stones was observed as 17%. This is in accordance with the studies given by Mohanty et al in 2004 [11] & Hamim et al [14] in 2010 where the frequency of gall stones were found to be 22% & 17% respectively.

However higher frequency of gall stones were found in studies given by Ali Balci et al in 2004 [10] as 30.4%. A lower frequency of gall stone was observed in studies given by Bakhietta et al in 2010 [12] as 11.1%. A thickened gall bladder wall measures >3mm and typically has a layered appearance on ultrasonography. In our study Thickened GB wall have a prevalence of 6%. This is in accordance with the study given by DA Nzeh et al in 1989 [19], whereby the prevalence of thickened GB wall was 8.1%. In another study by Bakhietta et al in 2010 [12], the frequency of thickened GB wall was 2.2%.

Kidney

Renal enlargement is a common finding in patients with sickle cell disease as a result of glomerular hypertrophy & increased renal blood volume [16]. In our study the prevalence of renal enlargement was observed to be 29% which is in accordance with the study of Ali Balci et al in 2004 [10] where the prevalence of renal enlargement was given as 30.4%. Increase in renal echogenicity can be attributed to factors like renal papillary necrosis, high concentrations of iron deposits within the tubular epithelial cells, focal scarring & interstitial fibrosis in vasa recta system, glomerular hypertrophy and renal sclerosis [20, 21]. In our study the prevalence of increased renal medullary echogenicity was observed as 14%.

This concurs with the study of Ali Balci et al in 2004 [10], Mohanty et al in 2004 [11] & Namjosh et al [22], whereby the prevalence of increased renal medullary echogenicity was 15.7%, 16% & 13.8% respectively. A slightly higher frequency of increased renal echogenicity was seen in studies given by Walker et al in 1995 [18],

Research Article

Papadaki et al in 2003 [9] & Ibinaiye et al in 2013 [18] as 20%, 17.6% & 18.9% respectively.

Pancreas

Iron deposition in the pancreas or pancreatic hemosiderosis causes the pancreas to be echogenic on US. In our study, increased echogenicity of pancreas was observed as 3%. This concurs with the study done by Ali Balci et al in 2004 [10] in which echogenic pancreas was found in 3.9% patients.

Conclusion

Real time Ultrasonography should be established as a routine screening procedure in sickle cell disease patients and thereafter as a routine follow up measure. The early detection of pathological changes and immediate intervention measures reduces the morbidity and mortality, thereby increasing the life expectancy. More studies should be conducted to establish initial age limit for screening and for intervals of routine follow-up with respect to both homozygous and heterozygous karyotypes.

Funding: Nil

Conflict of interest: Nil

Permission from IRB: Yes

References

- Herrick JB. Peculiar elongated and sickle-shaped red blood corpuscles in a case of severe anemia. *Arch Int Med* 1910; 6:517–520
- Bunn HF. Induction of fetal hemoglobin in sickle cell disease. *Blood* 1999; 93:1787–1789.
- Rodgers GP. Overview of pathophysiology and rationale for treatment of sickle cell anemia. *Semin Hematol* 1997; 34:2–7.
- H. Lehman and M. Cutbush, "Sickle Cell Trait in Southern India," *British Medical Journal*, Vol. 1, No.4755, 1952, pp. 404-405
- Dick R, Watkinson A. The liver and spleen. In: Sutton D, ed. *Textbook of radiology and imaging*. 7thed New York: Elsevier, 2002; 737-786.
- Bhavna Dhingra, Suvasini Sharma, Devendra Mishra. 2009. Normal values of Liver and Spleen Size by Ultrasonography in Indian Children. PN:S097475590800697-1.

Research Article

7. Miletic D, Fuckar Z, Sustic A, Mozetic V, Stimac D, Zauhar G. sonographic measurements of absolute and relative length in adults. *JClinUltrasound*1998;26:185-189
8. Rumack CM, Wilson SR, Charboneau JW. Diagnostic ultrasound, 2nd ed. St. Louis, MO: Mosby, 1998:175-200
9. Papadaki MG, Kattamis AC, Papadaki IG, Menegas DG, Georgakopoulou TP, Mavrommati-Metaxotou A, et al. Abdominal ultrasonographic findings in patients with Sickel cell anemia and thalassemia intermedia. *PediatrRadiol* 2003;33:515-21
10. Balci A, Karazincir S, Sangün O, Gali E, Daplan T, Cingiz C. Prevalence of abdominal ultrasonographic abnormalities in patients with sickle cell disease. *DiagnIntervRadiol* 2008;14:133-7
11. Mohanty J, Narayan J, Bhagat S, Panda BB, Satpathi G, Saha N. sonologicevaluation of abdominal organs in sickle cell crisis in Western Orissa. *Indian Journal of Radiology and Imaging* 2004; 14:247-51
12. Bakhieta IT. Sonographic findings in Sudanese children with sickle cell anaemia. *J Diagn Med Sonography* 2010;6:281-5
13. Ma'aji SM, Jiya NM, Saidu SA, Danfulani M, Yunusa GH, Sani UM, Jibril B, Musa A, Gele HI, Baba MS, Bello S. Transabdominalultrasonographic findings in children with sickle cell anemia in Sokoto, North-Western Nigeria. *Niger J Basic ClinSci [serial online]* 2012 [cited 2013 Dec 17];9:14-7.
14. Hamim Abdul Rusheke. Abdominal ultrasonographic abnormalities in patients with sickle cell anaemia at muhimbili national hospital 2010; Muhimbili University of Health and Allied Science. ir.muhas.ac.tz:8080/jspui. http://hdl.handle.net/123456789/1046
15. Lane PA. Sickel cell disease. *PediatrClin North Am* 1996; 43:639–664
16. Ma'aji SM, Jiya NM, Saidu SA, Danfulani M, Yunusa GH, Sani UM, Jibril B, Musa A, Gele HI, Baba MS, Bello S. Transabdominalultrasonographic findings in children with sickle cell anemia in Sokoto, North-Western Nigeria. *Niger J Basic ClinSci [serial online]* 2012 [cited 2013 Dec 17];9:14-7
17. Ahmed H.Salem et al: “Sonographic assessment of splenic size in Saudi patients with Sickel cell disease” *Ann Saudi Med* 1998;18(3):217-220.
18. Ibinaiye PO, Babadoko AA, Yusuf R, Hassan AA. Renal complications of sickle cell anemia in Zaria, Nigeria: An ultrasonographic assessment. *West Afr J Radiol* 2013;20:19-22
19. D.A. Nzeh& M.A. Adedoyin et al. sonographic pattern of gall bladder disease in children with sickle cell disease. *PediatrRadiol* (1989) 19:290-292.
20. Namjoshi SP. Punctate echogenic foci in spleen and increase echogenicity in renal cortex in sickle cell Ameamia. *J Clin Ultrasound* 1999;27:52
21. Walker TM, Searjeant GR. Increased renal reflectivityin sickle cell disease: prevalence and characteristics. *ClinRadiol* 1995; 195:566–569.
22. Namjoshi SP. Punctate echogenic foci in spleen and increase echogenicity in renal cortex in sickle cell Ameamia. *J Clin Ultrasound* 1999;27:52.

.....

How to cite this article?

Kaushal L, Verma VK, Ahirwar CP, Patil A, Singh SP. Sonographic evaluation of abdominal organs in a sickle cell disease patient. *Int J Med Res Rev* 2014;2(3):202-208. doi:10.17511/ijmrr.2014.i03.09

.....