

Skeletal Maturation in the pediatric population in a large tertiary care hospital in South India

Vijayalakshmi G.¹, Rajiah J.²

¹Dr Vijayalakshmi G, Professor of Radiology, Institute of Child Health & Hospital for Children, Chennai, ²Dr Jeya Rajiah, Associate Professor, Tirunelveli Medical College, Tirunelveli, Tamilnadu, India.

Address for Correspondence: Dr Vijayalakshmi G, Professor of Radiology, Institute of Child Health & Hospital for Children, Chennai, Address: 51, Officers Lane, Cantonment Pallavaram, Chennai. Email: drviji.rad@gmail.com

.....

Abstract

Background & Objectives: Determination of skeletal age is an important part of examination for many clinical problems with growth disorders. The Greulich and Pyle atlas method and the Tanner Whitehouse technique are used to assess bone age accurately. However time constraints force pediatricians to quickly assess bone age from age of appearance of epiphyseal centres. The aim of this study was to re-examine this method in today's clinical practice to enable more practical and appropriate use. **Methods:** The study was undertaken in The Institute of Child Health and Hospital for Children, Egmore, (ICH & HC) Chennai. Normal children less than 12 years were included in the study. The children were grouped in different age groups, 100 girls and 100 boys in each age group totalling 3800 children. Depending on the chronological age of the child only the x ray films of the hand, wrist, elbow, or knees were taken. We used x-rays of hands for all age groups and elbow in those over 5 years. Only the appearance of ossification centers was noted. We also used x-ray of the patella for children in 3 to 5 year age groups. **Results:** We found that the mean age of appearance of patellar ossification was similar in both boys and girls (mean age 4.8 ± 0.5). By 3-6 months capitata and hamate were present in all children (mean age 0.5 ± 0.1). There is high variability in the timing of ossification of carpal bones, which accounts for their elimination for age evaluation. However the pisiform follows a constant mean age at 10.6 for girls and 11.6 for boys. **Conclusion:** Children can be adequately screened for age assessment from x rays of the hands in the early stages (upto 2 and half years) and later the elbows. We propose the use of knees lateral for patellar centre for children more than 3 and less than 6.

Key words: Skeletal Maturation, skeletal age, Pediatric population

.....

Introduction

Determination of skeletal maturity is a part of medical examination for many clinical problems. The oldest method noted the age of appearance of epiphyseal centres in x-rays. Later, the Greulich and Pyle [1] atlas method and the Tanner and Whitehouse [2] scoring technique were based on the changes in the forms of ossification centres in the course of growth. These two methods have improved accuracy and revolutionised skeletal age assessment [3].

However many clinicians, paediatricians and radiologists still assess age based on the first method.

Reasons proffered are a lack of time to pore over atlases and requirement for a quick reckoner that will help in preliminary sorting of cases regarding skeletal maturation status. Another reason for continued use of our method is because skeletal maturity varies as much as two years on either side of the chronological age of normal healthy children between 5 and 14 years [2]. For initial diagnoses a discrepancy with the chronological age of 2 to 3y is the order of detection required [4]. If this is the case we have found that our method could be very useful.

This study reexamines the method, dispels certain myths [5, 6] and offers modification to enable more sensible use.

Manuscript received 20th September 2016
Reviewed: 4th October 2016
Author Corrected: 16th October 2016
Accepted for Publication 31st October 2016

Methods

Place of study- The study was undertaken in The Institute of Child Health and Hospital for Children, Egmore (ICH & HC) Chennai which holds the distinction of being the largest hospital for children in Asia. Study period- The study period extended from 2006 to 2013. Sampling- Consecutive sampling Children taken into the study were those attending OP for simple ailments.

Inclusion Criteria- Children less than 12 years (y) of age. Acute respiratory illnesses less than a week were also included. Only those children with weights and height falling within normal, according to the NCHS growth charts [7] (between 3rd and 97th percentile curves), were taken into the study.

Exclusion criteria- Adolescents were excluded. ICH & HC does not cater to children more than twelve years of age. Consequently only the appearance of ossification centers and not the fusion is noted. Children with history of serious illness like fever of more than four weeks, acute or chronic renal failure, glomerulonephritis or treatment for leukaemias, those with gross physical and mental defects were excluded.

Statistical analysis- Descriptive statistical analysis was done. Mean, Range, Standard Deviation and percentile values for 5th, 50th and 95th percentiles were derived 92% of children were Tamil and the rest were from South Andhra (7%), Odisha and Kerala (1%).

After ascertaining that the children satisfied the inclusion criteria, specific x-rays were taken.

Based on observations over many years and recorded standards of appearance of specific ossification centers certain x rays were taken so that maximum useful information is obtained with minimum of exposures.

Depending on the chronological age of the child only x ray films of the hand, wrist, elbow, or knees were taken.

Results

The third and fourth proximal phalanges appear by 1 year 9 months. All the centres of the 3rd and 4th phalanges were present by 2 years & 3 months. The 5th middle phalanx appears at the same time but the proximal and distal phalanges are delayed up to 3 years 9 months.

The carpal bones show a wide variation in their age of appearance, however the pisiform is quite constant and shows a mean age of appearance of 10 years and 6 months in girls and 11 years 6 months in boys.

1. Both hands with wrists AP – all children.
2. Three years and more- both knees lateral is also taken. The knees may be excluded in children over 6y if maturation in the elbow is proceeding normally eg: if ossification centre for radial head has appeared.
3. Five years and more- both elbow x rays is added to the hands.

Both sides were x rayed but there is no difference between the sides as was evident in our study. This is in agreement with other authors [1]. Any one side may be taken. The age groups are from the new born up to 12 years. Actual ages were noted since correct date of birth is known. While some may be evaluated in the beginning of the chronological year others may be examined in the latter half of the year. On a practical level, appearance and size of the previously appearing centres will help an observer in coming to a conclusion whether growth is proceeding normally. In our study only the appearance of centres were noted.

This is an easy observation which could be made by any new or unfamiliar observer. It is an objective decision.

There is no matching from atlases. The children were divided and grouped into three month intervals up to one year, then six monthly intervals up to 5 years and then annually up to 12 years. The number of groups therefore is 19. 100 children in each group were studied.

Boys and girls were recorded separately. 100 boys and 100 girls in each age group totalled to 3800.

The varying intervals of time are due to the fact that the skeletal development of the hand does not progress rapidly enough after age of five, to warrant more frequency than annual intervals [2]. This might not be true around puberty [8]. The appearance of the ossification centres were noted and entered into tabular columns for computation.

Table-1: Descriptive statistics for various parameters for boys.

PERCENTILE					
PARAMETER	MEAN±SD	5 th	50 th	95 th	RANGE
C1	0.50±0.18	3m	6m	6m	3m-6m
C2	0.98±1.24	3m	6m	6m	3m-6m
C3	4.23±1.43	2y9m	4y3m	7y6m	2y9m-7y6m
C4	5.97±1.39	4y3m	5y6m	9y6m	4y3m-9y6m
C5	7.48±1.10	6y6m	7y6m	9y6m	6y6m-9y6m
C6	7.87±1.00	6y6m	7y6m	9y6m	6y6m-9y6m
C7	8.47±0.95	6y6m	8y6m	9y6m	6y6m-9y6m
DR	1.53±0.30	1y3m	1y9m	1y9m	1y3m-1y9m
MC1	3.03±0.51	2y9m	3y0m	4y0m	2y9m-4y0m
MC2	1.92±0.36	1y3m	1y9m	2y3m	1y3m-2y3m
MC3	1.97±0.35	1y3m	2y3m	2y3m	1y3m-2y3m
MC4	1.95±0.35	1y3m	2y3m	2y3m	1y3m-2y3m
MC5	1.99±0.34	1y3m	2y3m	2y3m	1y3m-2y3m
PP1	2.93±0.43	2y3m	3y3m	3y3m	2y3m-3y3m
PP2	2.29±0.79	1y3m	1y9m	3y3m	1y3m-3y3m
PP3	1.85±0.44	10m	1y9m	2y3m	10m-2y3m
PP4	1.86±0.43	10m	1y9m	2y3m	10m-2y3m
PP5	2.79±0.72	1y9m	2y9m	3y9m	1y9m-3y9m

Table-2: Descriptive statistics for various parameters for boys.

PERCENTILE					
PARAMETER	MEAN±SD	5 th	50 th	95 th	RANGE
DP1	1.87±0.38	10m	1y9m	2y3m	10m-2y3m
DP2	3.22±0.61	1y9m	3y3m	3y9m	1y9m-3y9m
DP3	1.65±0.20	1y3m	1y9m	1y9m	1y3m-1y9m
DP4	1.66±0.20	1y3m	1y9m	1y9m	1y3m-1y9m
DP5	3.25±0.63	1y9m	3y3m	3y9m	1y9m-3y9m
MP2	2.24±0.45	1y9m	2y3m	2y9m	1y9m-2y9m
MP3	1.94±0.27	1y9m	1y9m	2y3m	1y9m-2y3m
MP4	1.95±0.28	1y9m	1y9m	2y3m	1y9m-2y3m
MP5	1.82±0.23	1y4m	1y9m	2y3m	1y4m-2y3m
Med epi	8.37±1.06	6y6m	8y6m	9y6m	6y6m-9y6m
Pis	11.12±0.70	9y6m	11y6m	11y6m	9y6m-11y6m
Olec	10.96±0.87	8y6m	11y6m	11y6m	8y6m-11y6m
Ul sty	9.98±0.96	7y6m	10y6m	10y6m	7y6m-10y6m
DU	8.32±1.21	6y6m	8y6m	9y6m	6y6m-9y6m
Lat-epi	10.90±0.84	9y6m	11y6m	11y6m	9y6m-11y6m
Troch	10.94±0.81	9y6m	11y6m	11y6m	9y6m-11y6m
Rad-hea	7.09±0.49	6y6m	7y6m	7y6m	6y6m-7y6m
Pat	4.86±0.52	4ys3m	4y9m	5y6m	4y3m-5y6m

The mean age of appearance of distal radius was 1year 6months ± 3 months. The distal ulna had a wide range of appearance (6.6- 9.6 for boys & 5.6-9.6 for girls.) The Ulnar styloid also had a wide range of appearance. The olecranon

showed a mean of 10.9 ± 0.8 in boys and 10.3 ± 1 in girls. The 50th and 95th percentile of the radial head was 6y 6m and 7y 6m in girls respectively and in boys both 50th and 95th percentile was 7y 6m. The 50th & 95th percentile for boys & girls for medial epicondyle was 8y 6m and 9y 6m respectively. DP- distal phalanx We found that the mean age of appearance of patellar ossification was similar in both boys and girls (mean age 4.8 ± 0.5).

PP	-	proximal phalanx
MP	-	middle phalanx
DP	-	distal phalanx
Med epi	-	medial epicondyle
Pis	-	pisiform
Olec	-	olecranon
Ul sty	-	ulnar styloid
DU	-	distal ulna
Lat epi	-	lateral epicondyle
Troch	-	trochlea
Rad head-	-	radial head
Pat	-	patella
DR	-	distal radius
C1	-	capitate
C2	-	hamate
C3	-	triquetrum
C4	-	lunate
C5	-	scaphoid
C6	-	trapezium
C7	-	trapezoid
MC	-	metacarpal

Table-3: Descriptive statistics for various parameters for girls.

PARAMETER	MEAN±SD	PERCENTILE			RANGE
		5 th	50 th	95 th	
C1	0.25±0.00	3m	3m	3m	3m-3m
C2	1.66±1.92	3m	3m	6m	3m-6m
C3	4.03±1.19	2y9m	3y3m	6y4m	2y9m-6y4m
C4	5.07±1.45	3y3m	4y9m	6y6m	3y3m-6y6m
C5	7.13±1.98	4y3m	7y6m	9y6m	4y3m-9y6m
C6	6.18±1.60	4y3m	5y6m	9y8m	4y3m-9y8m
C7	7.87±1.10	5y6m	7y6m	9y8m	5y6m-9y8m
DR	1.52±0.28	1y3m	1y9m	1y9m	1y3m-1y9m
MC1	3.23±0.52	2y3m	2y6m	3y6m	2y3m-3y6m
MC2	1.86±0.40	1y3m	1y9m	2y3m	1y3m-2y3m
MC3	1.85±0.39	1y3m	2y3m	2y3m	1y3m-2y3m
MC4	1.85±0.40	1y3m	2y3m	2y3m	1y3m-2y3m
MC5	1.93±0.40	1y3m	2y3m	2y3m	1y3m-2y3m
PP1	2.72±0.47	2y3m	2y9m	3y3m	2y3m-3y3m
PP2	1.97±0.77	10m	1y9m	3y3m	10m-3y3m
PP3	1.65±0.48	10m	1y9m	2y3m	10m-2y3m
PP4	1.67±0.49	10m	1y9m	2y3m	10m-2y3m
PP5	2.12±0.53	1y3m	2y3m	2y9m	1y3m-2y9m

Table-4: Descriptive statistics for various parameters for girls.

PARAMETER	MEAN±SD	PERCENTILE			RANGE
		5 th	50 th	95 th	
DP1	1.88±0.49	10m	2y3m	2y3m	10m-2y3m
DP2	2.94±0.90	1y3m	3y3m	3y9m	1y3m-3y9m
DP3	1.43±0.24	1y3m	1y3m	1y9m	1y3m-1y9m
DP4	1.43±0.24	1y3m	1y3m	1y9m	1y3m-1y9m
DP5	3.12±0.75	1y3m	3y3m	3y9m	1y3m-3y9m
MP2	2.10±0.50	1y3m	2y3m	2y9m	1y3m-2y9m
MP3	1.85±0.38	1y3m	1y9m	2y3m	1y3m-2y3m
MP4	1.84±0.39	1y3m	1y9m	2y3m	1y3m-2y3m
MP5	1.88±0.37	1y3m	1y9m	2y3m	1y3m-2y3m
Med epi	8.16±1.08	6y6m	8y6m	9y6m	6y6m-9y6m
Pis	10.54±0.95	8y6m	10y6m	11y6m	8y6m-11y6m
Olec	10.39±1.08	8y6m	10y6m	11y6m	8y6m-11y6m
Ul sty	9.40±1.08	7y6m	9y6m	10y6m	7y6m-10y6m
DU	8.15±1.27	5y6m	8y6m	9y6m	5y6m-9y6m
Lat-epi	10.75±0.89	9y6m	11y6m	11y6m	9y6m-11y6m
Troch	10.95±0.84	9y6m	11y6m	11y6m	9y6m-11y6m
Rad-hea	7.00±0.50	6y6m	6y6m	7y6m	6y6m-7y6m
Pat	4.85±0.52	4y3m	4y9m	5y6m	4y3m-5y6m

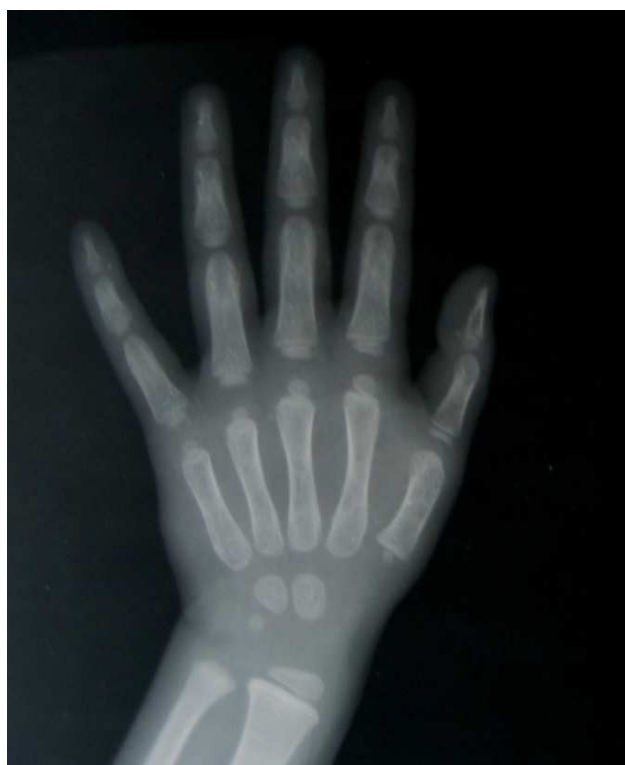

Fig-1: The first metacarpal is seen in this 3 year old

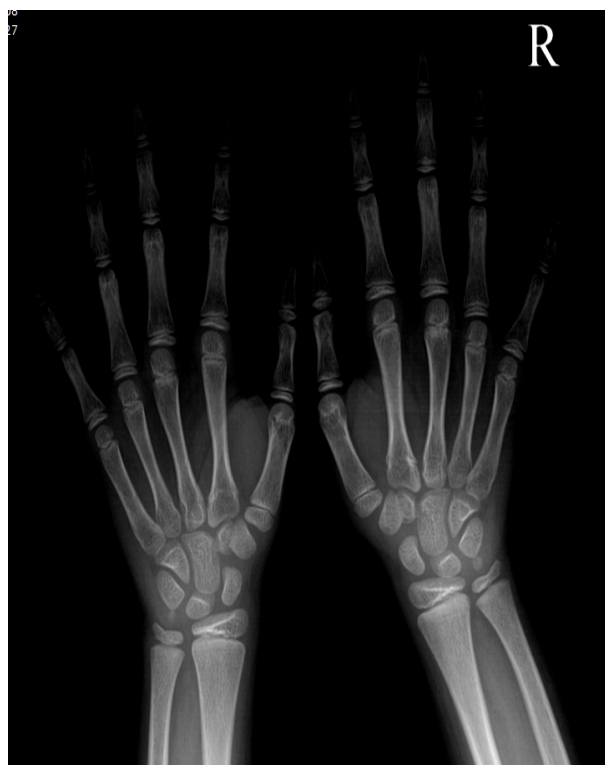

Fig-2: The pisiform is seen in this 10 year old girl

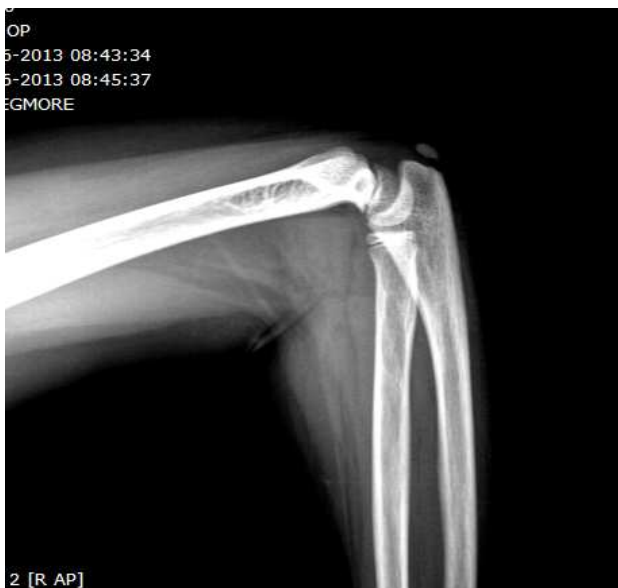

Fig-3: Olecranon centre in a 11year old girl

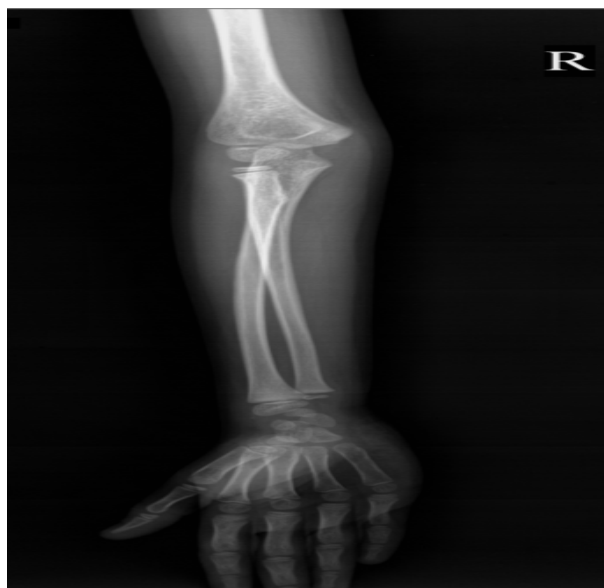

Fig-4: The radial head and medial epicondyle is seen in this 7 year old boy

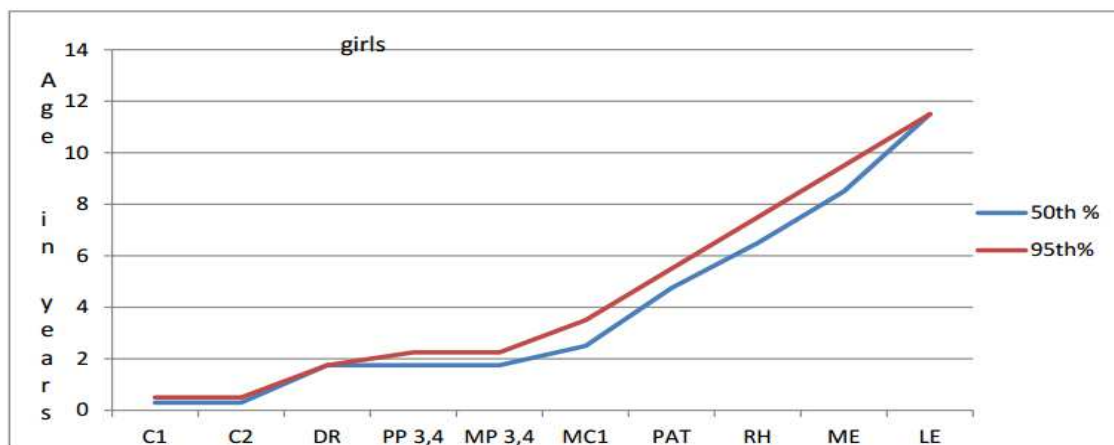


Fig 5- 50th and 95th percentile of ossification centres in girls

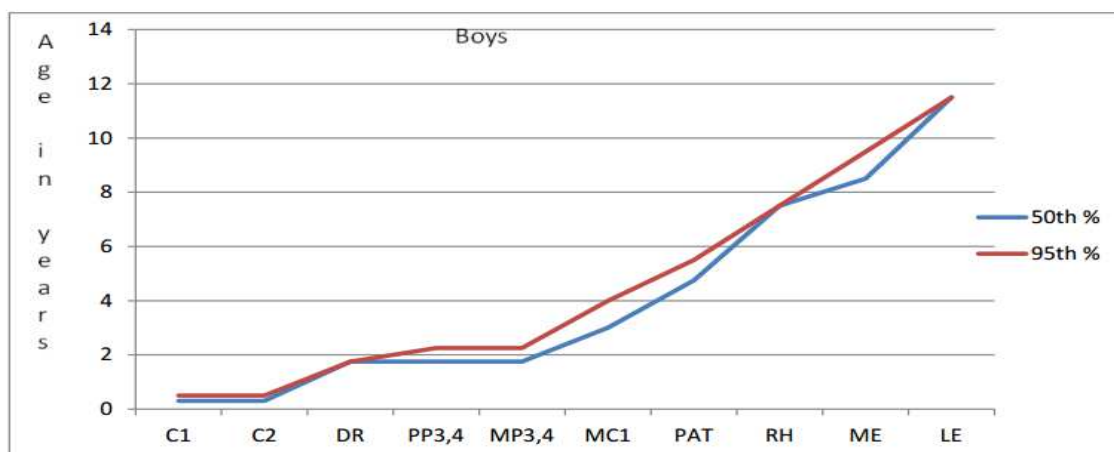


Fig 6- 50th and 95th percentile of ossification centres in boys

Discussion

The x-rays of the hands has traditionally been used to study bone age. The large number of centers in the hand and the different times of their appearance were baffling to many which lead to an arbitrary notion of deducing age based on just the number of carpal bones seen [5]. The elbow also has a number of epiphyses that are readily seen in the antero-posterior and lateral (for olecranon centre) views. Thus, these two regions enable the study of many centres. The patella is not generally noted in textbooks of forensic medicine but many workers have studied its appearance. It is seen to show great constancy and that is why this was also included in our study.

Carpal bones: A widely held presumption that the age of the child is equal to the number of carpal bones plus two is baseless as seen in the study. The capitate and hamate are present at birth, the 95th percentile level being reached at 3m in girls and 6m in boys. The next appearing triquetrum may be present by 2y 9m but can be as late as 7y 6m in boys and 6y 4m in girls. The lunate can be delayed as long as 6y 6m in girls and 9y 6m in boys. The same variability can be said of other carpal bones, except the pisiform. Maniar [9] also found a wide spectrum in the appearance of carpal bones. This is sufficient evidence to discard the old formula of the number of carpals and age.

Pisiform- The pisiform center was reported by Bajaj et al [10] at 13 years for boys and 10y 3m for girls. The western standards [11] give a mean of 9y 9m for boys and 8y for girls. Our 50th percentile was 10y 6m for girls and 11y 6m for boys, a reading approaching western levels. In the Greulich and Pyle atlas [1] the pisiform is seen at 9y 6m years in girls and 10 in boys.

When we consider this with our 5th percentile values the global secular trend in growth and development is seen in the advance by 6 months in our boys. There is an additional advance of one year in our girls probably due to the added factor of early pubertal growth spurt.

Olecranon- Our 50th percentile values were 10.3 for girls and 10.9 for boys. The fifth percentile was 8.6 for boys and girls. In practice it can be timed at 8 to 10 y.

Capitulum- The capitulum was present in all the films at the time elbow x-rays were included in the age groups. The timing of appearance is around a year.

Patella- Garn's [11] 7.6-6 years in boys, and 2 to 4 in girls are very different from ours. Our values range from 4y 6m to 5y 6m in both boys and girls. The patella is not taken into account by Greulich and Pyle [1] whose study is only of the hands. Bajaj et [10] al do not mention the patella.

Acheson [12] applied the Oxford maturity units to the patella. But the frequency distribution was very irregular and was not followed. We propose that the patella would be a helpful indicator for age estimation since it falls between the time of appearance of hand centers (excluding carpals) and that of elbow centers. If patella is seen the child has crossed four years. In the study by Garn [11] the difference between boys and girls was very wide. The range for boys was 5 to 6 and girls 2y 6m to 4y. But this wide difference was not seen in our children and none of our girls had the patella at Garn's [11] value of 2.6 years. Therefore, there is a great constancy in the appearance of the patella by around 4y. Variability is minimal.

There is no difference between boys and girls and the patella serves to bridge the gap between timing of hand and elbow centers.

Distal Radius- Bajaj and Bharadwaj [10] showed a wide range of 1.7 to 3.5 in girls. According to western standards [11] the distal radius can show up as early as 9 to 10 months. In our study the 50th percentile and the 5th percentile was at 1y 9m, the same for both sexes. By two years, it was definitely present. In practice it can be timed at one and half to two years.

Distal Ulna and Ulnar styloid- Bajaj and Bharadwaj's [10], Garn's [11] study and ours showed wide range. These may be eliminated in routine practice.

Elbow- Another eponym for age evaluation on the basis of centres in the elbow is CRITOE [5] designating the order of appearance as capitulum, radial head, internal epicondyle, trochlea, olecranon and external epicondyle. According to this, the capitulum ossifies by age 1 and two years is added for the appearance of each successive ossification center. This scheme is far from accurate as you will see below.

Trochlea- The trochlea appears at 9-11 years in agreement with forensic medicine textbooks, [13, 14].

Medial epicondyle- The 50th percentile for us was at 8y 6m corresponding to the value of 7 to 8 years in V.V. Pillay's textbook of forensic medicine [13]. In Narayana Reddy's Forensic Medicine [14], the value is different at 6-7y. This shows the lack of uniformity in values even in Indian books. Western levels [11] are too early, earliest of 3y 6m in girls. None of our children had the medial epicondyle at 3-4y. In routine practice the medial epicondyle can be timed at 8 years.

Radial head- The 50th percentile in our study was 7.5 for boys and 6.6 for girls and this does not match with forensic textbooks at 5 years. Bharadwaj [10] reports means of 6y 2m for boys and 3y 6m for girls. No child in our study had radial head at 5y. Garn's 50th percentile values were also too early at 4y for boys and 3y for girls. We time the radial head at 6 to 7y and is quite a constant in day to day practice.

Lateral epicondyle-In 1970[10], its appearance was 9 to 14 in boys and 7-12 in girls 5. By 1980, the lateral epicondyle was seen at 13-14y (unpublished data-Elizabeth John). In our study it was seen by 11y 6m. The center can appear as early as 9 years in both sexes, but it is definitely seen by 11y 6m.

This is very clear evidence for the general improvement in the socio-economic status and nutrition that has led to quicker skeletal maturation so that we now equal the western standards of Garn. The advancement in puberty due to better nutrition is also another cause for the quicker skeletal maturation.

Hands- Forensic medicine textbooks [13,14] put down the age of appearance of phalangeal centers as two to four years. While the third and fourth proximal phalanges can appear as early as 10m, the 50th percentile is at one year 9m. All the centres of the third and fourth fingers are present by two years three months. The tables show we are close to values seen in the Greulich and Pyle atlas.

The first metacarpal follows a different timetable. In Greulich and Pyle's atlas, the first metacarpal centre is seen at 2y 8m in boys and 2y in girls. Bajaj's Delhi population [10] showed a great difference- 4y 2m in boys and 2y 1m in girls. Forensic medicine textbooks club the first metacarpal with the other metacarpals. But the first metacarpal can be used as a marker for 2y 6m to 3y. The centre can appear as early as 2y in girls and 2y 9m in boys.

Conclusion

There may be many a debate between the Greulich and Pyle atlas method and the more accurate TW2 method. But, the age old method of telling age based on only the time of appearance of epiphyseal centers is still being used. Re- examination of the technique has revealed a positive secular trend in growth of our children. We consider only a few of these centres to come to a conclusion of whether the child is progressing normally towards maturity or not. The atlas method and the TW2 method requires proper positioning of the hands, time to interpret and trained manpower to help in the interpretation- all of which are practically not often possible.

There is also software for automated measurement of bone age on the net (boneXpert- www.bonexpert.com) that can assess age on online submission of an x-ray of the hands. This requires a payment in pounds. Our method is a quick method, requires no training and is easily incorporated into the routine OP situation. For those of us who are concerned with initial diagnoses and quick separation of those with growth disorders, this method continues to be a useful tool.

Further accurate assessment can be done by the TW2 method which might be necessary if endocrine treatment is started or if final height is to be predicted in case of planning certain orthopedic procedures.

Funding: Nil, **Conflict of interest:** None initiated, **Permission from IRB:** Yes

References

1. Greulich WW, Pyle SI. Radiographic Atlas of skeletal development of hand and wrist. Stanford: Stanford University Press 1950 (reprint 1954).
2. Tanner JM, Whitehouse RH, Marshall WA, Goldstein H. Assessment of skeletal maturity and prediction of adult height. London: Academic Press, 1975.
3. Bull RK, Edwards PD, Kemp PM, Fry S, Hughes IA. Bone age assessment: a large scale comparison of the Greulich and Pyle, and Tanner and Whitehouse (TW2) methods. Arch Dis Child. 1999 Aug;81(2):172-3.
4. Buckler JM. How to make the most of bone ages. Arch Dis Child. 1983 Oct;58(10):761-3.

5. Goyal A, Gaillard F. Elbow ossification. Available at <https://radiopaedia.org/articles/elbow-ossification>.
6. Satoh M. Bone age: assessment methods and clinical applications. *Clin Pediatr Endocrinol*. 2015 Oct;24(4): 143-52. doi: 10.1297/cpe.24.143. Epub 2015 Oct 24.
7. Khadilkar V, Khadilkar A. Growth charts: A diagnostic tool. *Indian J Endocrinol Metab*. 2011 Sep; 15 Suppl 3:S166-71. doi: 10.4103/2230-8210.84854.
8. Flor-Cisneros A, Leschek EW, Merke DP, et al: In boys with abnormal developmental tempo, maturation of the skeleton and the hypothalamic- pituitary – gonadal axis remains synchronous. *J Clin Endocrinol Metab* 2004; 89 (1): 236 – 41.
9. Maniar B. Skeletal maturity in Indian children. *Indian J Pediatr*. 1987 May-Jun;54(3):295-302.
10. Bajaj ID, Bhardwaj OP, Bhardwaj S. Appearance and fusion of important ossification centres: a study in Delhi population. *Indian J Med Res*. 1967 Oct; 55 (10):1064-7.
11. Garn SM et al *Med Radiogr Photogr in Caffey's Pediatric Radiology XIth edition* 2008.
12. Acheson RM, Kemp JH, Parfit J. Height, weight, and skeletal maturity in the first five years of life. *Lancet*. 1955 Apr 2;268(6866):691-2.
13. VV Pillay, Chap 4 in *Textbook of Forensic Medicine and Toxicology*; 14th Edition Paras Publishers Hyderabad 2004.
14. Dr. KS Narayana Reddy, Chapter 4 in *The Essentials of Forensic Medicine and Toxicology* 24th Edition Published by Suguna Devi Hyderabad 2005.

.....

How to cite this article?

Vijayalakshmi G, Rajiah J. Skeletal Maturation in the pediatric population in a large tertiary care hospital in South India. *Int J Med Res Rev* 2016;4(10):1838-1846.doi:10.17511/ijmrr. 2016.i10.21.

.....