

## Apert syndrome: A Case report

Kosam A<sup>1</sup>, Nehrel R<sup>2</sup>

<sup>1</sup>Dr Ajay Kosam, Assistant Professor, <sup>2</sup>Dr Rakesh Nahrel, Associate Professor. Both affiliated with Department of Pediatrics, Chhattisgarh Institute of Medical Sciences, Bilaspur, Chhattisgarh, India

**Address for correspondence:** Dr Ajay Kosam, Email: kosamajay@gmail.com

### Abstract

Apert syndrome or Acrocephalosyndactyly is a rare congenital disorder that affects the craniofacial structures and the limbs and is characterized by bicoronal synostosis, midface hypoplasia and complex syndactyly of the hands and feet. We report a neonate who had clinical and radiological features consistent with Apert syndrome.

**Key Words:** Apert syndrome, Brachycephaly, Syndactyly, Synonychia

### Introduction

Apert syndrome is a rare congenital anomaly characterized by craniosynostosis, craniofacial anomaly and severe symmetrical syndactyly of hands and feet. It is classified as a brachial arch syndrome affecting the first brachial arch the precursor of the maxilla and mandible.<sup>1-3</sup>

### Case Report

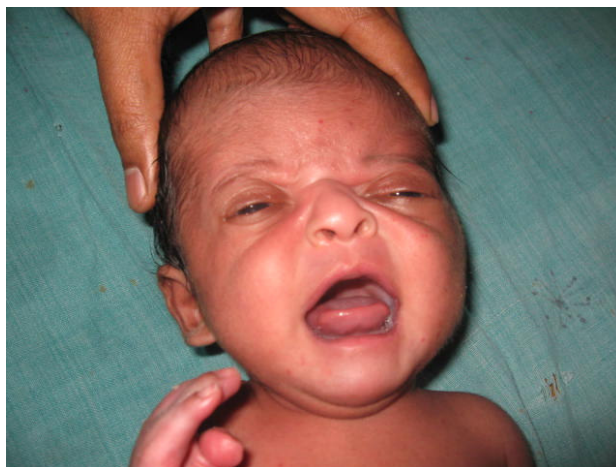
A full term male baby was born through normal vaginal delivery to a 29 year old mother and 30 year old father, third sibling in the family of a non consanguineous marriage. Pregnancy was uneventful with no known exposure to any irradiation, drugs, and infections during

antenatal period. No similar condition in the family (siblings or parents) was reported. On admission the birth weight of the baby was 3.34 kg, length was 53 cm, upper segment measures 32 cm, head circumference was 34 cm and chest circumference was 33 cm.

Baby had respiratory distress due to upper airway obstruction requiring supplemental oxygen and supportive care for 3 days.

The facial features were characteristic with down thrust eyes, a flat nasal bridge, and hypertelorism with an antimongoloid slant, bulging of the eyes secondary to the shallow orbits, low set ears and short wide nose with bulbous tip. The skull showed high prominent forehead, brachycephaly and flat occiput with synostosis of coronal sutures and widely patent fontanelles. (Fig.1)

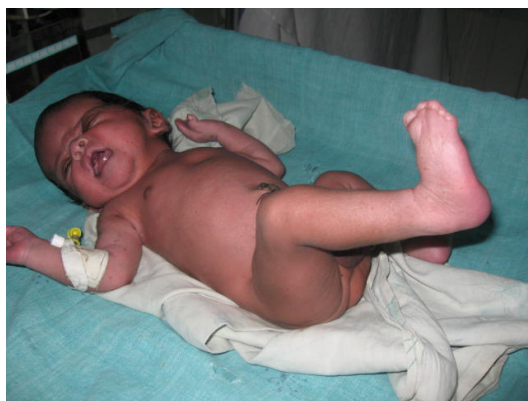Manuscript received: 14<sup>th</sup> Dec 2013  
Reviewed: 19<sup>th</sup> Dec 2013  
Author Corrected: 25<sup>th</sup> Dec 2013  
Accepted for Publication: 11<sup>th</sup> Jan 2014



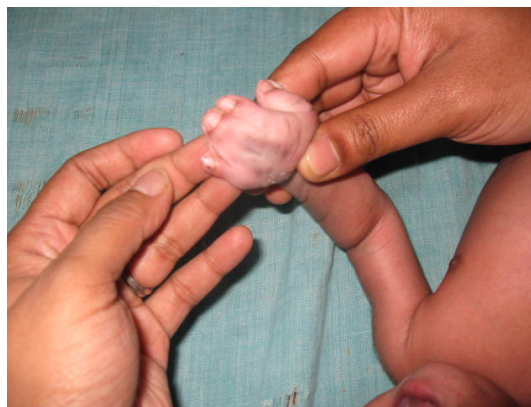**Fig 1:** Facial Features suggesting of Apert Syndrome

**Case Report**

The baby has severe symmetrical syndactyly of all the fingers and toes, radial deviation of short broad thumbs and contiguous nail beds (Synonychia) of the middle and ring fingers. The syndactyly was marked and resembled 'mitten hand' and 'sock foot' (fig. 2 and 3).



**Fig 2:** Syndactyly with Sock foot



**Fig 3:** Syndactyly in hands with synonychia

There was a flexion deformity of the elbows with flexion deformity of both hands. The palmar aspect was spoon shaped. The feet showed a varus deformity with syndactyly of all toes and Synonychia. The other systems showed no abnormality. Roentgenographic examination of the bony skeleton revealed an acrocephaly with fusion of the metacarpals at their proximal ends and the terminal phalanges at their distal ends. CT scan of whole body shows no other abnormalities.

**Discussion**

Apert syndrome is a genetic disorder inherited in an autosomal dominant pattern. Almost all cases of Apert syndrome result from a sporadic or spontaneous mutation in the gene, and occur in people with no history of the disorder in their family.<sup>4</sup> People suffering with Apert syndrome, however, can pass along the condition to the next generation.

Mutations in the fibroblast growth receptor 2 ( FGFR2) gene which is on chromosome number 10 cause Apert syndrome.<sup>5-8</sup> FGFR2 gene produces a protein which signals immature cells to become bone cells during embryonic development.

A mutation in FGFR2 gene alters this protein and causes prolonged signaling. This leads to increased subperiosteal bone matrix formation which can promote the premature fusion of bones in the skull, hands, and feet.

Increased paternal age has been noted to be a risk factor for Apert syndrome.<sup>9</sup> Males and females are equally affected.

Apert syndrome affects an estimated 1 in 65,000 to 88,000 newborns.<sup>10</sup> Apart from the characteristic facial features, the mouth area has a prominent mandible, high arched palate, bifid uvula, cleft palate and various orthodontic problems. Upper limbs are more severely affected than lower limbs. There is coalition of distal

phalanges and Synonychia in hands. The glenohumeral joint and proximal humerus is more severely affected than the pelvic girdle and femur. Syndactyly involves the hands and feet with partial to complete fusion of the digits, often involving 2<sup>nd</sup>, 3<sup>rd</sup> and 4<sup>th</sup> digits termed mitten hands and sock feet.

In severe cases all digits are fused, with the palm deeply concave and cup shaped and the sole supinated. Hitchhiker posture or radial deviation of short and broad thumbs results from abnormal proximal phalanx. Nail beds are contiguous (Synonychia).

Mobility at glenohumeral joint and elbow joint is limited.

Other skeletal defects include congenital cervical spine fusion, especially C5-C6 (68% cases).

Cardiovascular anomalies are seen in 10% cases<sup>11</sup> which include ASD, VSD, PDA, PS, TOF, COA etc.

Genitourinary anomalies are seen in 9.6% cases<sup>11</sup> ranging from polycystic kidney, hydronephrosis, duplication of renal pelvis etc.

Gastrointestinal and respiratory system anomalies are uncommon seen in 1.5% cases<sup>11</sup> which include pyloric stenosis, esophageal atresia and trachea-esophageal fistula, imperforate anus, pulmonary aplasia etc.

**Case Report**

In reported cases the age incidence varies from 4 months to 9 years but in our case the characteristic craniofacial and limb anomalies are recognizable at birth.

The baby had features of upper airway obstruction in the immediate neonatal period which usually occurs in most patients during infancy due to reduced nasopharyngeal size and choanal patency.

Mortality and morbidity in children with Apert syndrome is due to upper airway as well as lower airway compromise causing early death, obstructive sleep apnea and cor pulmonale.

Elevated ICP due to craniostenosis is another cause of mortality. Many patients exhibit mental retardation but patients with normal intelligence have been reported.

Management of Apert syndrome requires multidisciplinary approach.<sup>12</sup>

Medical management of Apert syndrome includes corneal protection by instilling lubricating eye ointments and artificial tear drops.

Management of upper airway obstruction by suctioning humidified oxygen and topical nasal decongestants and Sleep apnea management by polysomnography and continuous positive pressure.

Antibiotic treatment is required for chronic middle ear effusion.

Surgical management includes corneal protection by lateral and medial tarsorrhaphy, tracheostomy for severe airway obstruction, cranial, orbital, nasal, midfacial and mandibular surgery to correct craniofacial deformities and to improve survival<sup>13</sup>.

**Conclusion**

There is no cure for Apert syndrome, but early clinical diagnosis, prompt supportive treatment and timely referral to multidisciplinary centre can offer these children a chance of obtaining a more normal facial appearance and the opportunity to grow, develop, and integrate socially with their peers.

Discovery of mutation in FGFR genes now allows the definitive antenatal diagnosis of Apert syndrome and other craniosynostosis syndromes and skeletal dysplasia.

This will allow for appropriate family counseling and perhaps, in the future, gene therapy for the correction of the mutation.

**Funding:** Nil

**Conflict of interest:** Nil

**Permission from IRB:** Yes

**References**

1. Cohen MM Jr, Kreiborg S. A clinical study of the craniofacial features in Apert syndrome. *Int J Oral Maxillofac Surg.*1996 Feb; 25(1):45-53.
2. Cunningham ML, Seto ML, Ratisoontorn C, Heike CL, Hing AV. Syndromic craniosynostosis: from history to hydrogen bonds. *Orthod Craniofac Res.*2007 May; 10(2):67-81.
3. Park WJ, Theda C, Maestri NE, Meyers GA, Fryburg JS, Dufresne C. Analysis of phenotypic features and FGFR2 mutations in Apert syndrome. *Am J Hum Genet.*1995 Aug; 57(2):321-8.
4. Chang CC, Tsai FJ, Tsai HD, Tsai CH, Hseih YY, Lee CC. Prenatal diagnosis of Apert syndrome. *Prenat Diagn.*1998 Jun; 18(6):621-5.
5. Cohen MM Jr, Kreiborg S. An updated pediatric perspective on the Apert syndrome. *Am J Dis Child.* 1993;147:989-93
6. Wilkie AO, Wall SA. Craniosynostosis: novel insights into the pathogenesis and treatment. *Curr Opin Neurol.*1996;9:146-52
7. Chen L, Li D, Li C, Engel A, Deng CX. Ser250trp substitution in mouse fibroblast growth factor receptor 2 (FGFR2) results in craniosynostosis. *Bone.*2003;33:169-78
8. Wilkie AO, Slaney SF, Oldridge M, Poole MO. Apert syndrome results from localized mutation of FGFR2 and is allelic with Crouzon syndrome. *Nat Genet.*1995;9:165-72
9. Glaser RL, Broman KW, Schulman RL. The paternal-age effect in Apert syndrome is due, in part, to the increased frequency of mutations in sperm. *Am J Hum Genet.* 2003; 73:939-47.
10. Cohen MM Jr, Kreiborg S. New indirect method for estimating the birth prevalence of the Apert's syndrome. *Int J Oral Maxillofac Surg.*1992; 21:107-9.
11. Arroyo Carrera I, Martínez-Frías ML, Marco Pérez JJ. Apert syndrome: clinico-epidemiological analysis of a series of consecutive cases in Spain. *An Esp Pediatr.*1999; 51:667-72.

**Case Report**

12. Kaplan LC. Clinical assessment and multispecialty management of Apert syndrome. Clin Plast Surg.1991; 18:217-25.

13. Renier D, Lajeunie E, Arnaud E, Marchac D.Management of craniosynostosis. Childs Nerv Syst. 2000 Nov; 16(10-11):645-58.

.....  
**How to cite this article?**

Kosam A, Nahrel R. Apert syndrome -A Case Report. *Int J Med Res Rev* 2014;2(1): 63-66, 10.17511/ijmrr.2014.i01.11  
.....