

# Endoscopic evaluation and treatment of epistaxis – A prospective study

Swapna U.P.<sup>1</sup>, Simla S.R.<sup>2</sup>, Anjali R.<sup>3</sup>, Salil kumar K<sup>4</sup>

<sup>1</sup>Dr Swapna U. P, Assistant Professor, <sup>2</sup>Dr Simla S. R, Assistant Professor, <sup>3</sup>Dr Anjali R, Assistant Professor, <sup>4</sup>Dr Salil Kumar K, Professor and Head, Department of ENT, SUT Academy of Medical Sciences, Trivandrum, Kerala, India.

**Address of corresponding author:** Dr Swapna U.P, Email: swapnamanoj@gmail.com

## Abstract

Epistaxis is a common nasal symptom seen in all age groups. It often presents as an emergency. An attempt should always be made to find any local or systemic cause for it because epistaxis is a sign and not a disease per se. **Objectives:** To evaluate the local causes of epistaxis using rigid nasal endoscope for specific treatment planning. **Methods:** This was a prospective study which included 50 patients with epistaxis who attended the Otolaryngology outpatient department of SUT Academy of Medical Sciences, Trivandrum over a period of one year. Rigid nasal endoscopy under local anesthesia was done for these patients for whom both anterior and posterior rhinoscopy could not reveal any local causes. **Results:** Nasal endoscopy helped in finding the local causes for epistaxis. Epistaxis was more common in males (66%) and majority was in the age group of 21-30 years (46%). The causes were posterior deviation of nasal septum with spur (24%), bleeding points on the nasal septum (12%), rhinosporidiosis (10%), infected polyp (10%), deviated nasal septum with allergic rhinitis (8%), congested adenoids (8%), deviated nasal septum with sinusitis (4%), nasopharyngeal mass (4%), and miscellaneous conditions (6%). In 6% patients, no significant local cause was detected. All the patients were treated according to the endoscopic findings. **Conclusion:** Nasal endoscope is an important tool in diagnosis and treatment of local causes of epistaxis.

**Keywords-** Cauterization, Deviated nasal septum, Endoscopy, Epistaxis, Nasal polyp.

## INTRODUCTION

Epistaxis is defined as acute haemorrhage from the nostril, nasal cavity, or nasopharynx [1,2]. It is the most frequent emergency condition in otolaryngology department with a prevalence of 10-12% [3,4]. Epistaxis can be anterior or posterior. Anterior epistaxis is common in young individuals below 40 years. For people above 40 years, epistaxis is mainly from the posterior part of the nasal cavity. The causes can be local, systemic, or idiopathic. Local causes include causes in the nose, paranasal sinuses, or nasopharynx [1,2]. The systemic diseases such as hypertension, cirrhosis liver, nephritis and coagulopathies can also result in epistaxis. If no cause is detected clinically and after investigations, it is classified as idiopathic.

For effective therapeutic approach, it is important to know the nasal vascularization and prevalent bleeding sources. Nasal cavity is supplied by branches of internal

and external carotid arteries. The majority of the nasal cavity is supplied by the sphenopalatine artery which is a branch of external carotid artery. In many cases, with anterior and posterior rhinoscopy, it is difficult to find the local cause of epistaxis. With the advent of nasal endoscope, the diagnosis and treatment of epistaxis became easy. Nasal endoscope has superior lighting quality and magnification which give a detailed view of the nasal cavity and the covert areas of the nose situated in the deep crevices of the lateral nasal wall [5-7].

Messerklinger was the first to start endoscopic nasal and paranasal sinus surgery [3]. The use of endoscope during the last decade provided high quality visualization of the intranasal anatomy and improved the knowledge on the intranasal pathology [3,8]. Nasal endoscopy helps to identify the bleeding sources in the nasal cavity that are impossible to be seen by anterior and posterior rhinoscopy. During nasal endoscopy, bleeding points located in the posterior part of the nasal cavity can be cauterized effectively.

Manuscript received 26<sup>th</sup> April 2016  
Reviewed: 12<sup>th</sup> May 2016  
Author Corrected: 25<sup>th</sup> May 2016  
Accepted for Publication 11<sup>th</sup> June 2016

## MATERIALS AND METHODS

This was a prospective study conducted in the Otolaryngology Department of SUT Academy of Medical Sciences, Trivandrum from 2015 January to 2015 December. 50 patients with anterior and posterior epistaxis willing for nasal endoscopy were selected for the study.

### Inclusion criteria

- Patients of age group 10-60 years.
- Absence of any systemic diseases.

### Exclusion criteria

- Children less than 10 years, because it is difficult to do rigid nasal endoscopy under local anesthesia.
- Traumatic and post-operative epistaxis.
- Pregnant ladies.
- Epistaxis due to coagulopathies.

The study was approved by the institutional ethical committee. Informed consent was taken from all the patients who satisfied the inclusion criteria. In patients with active epistaxis, the first priority was to control the

bleeding by first aid measures or anterior nasal packing. Detailed medical and surgical history was taken. This was followed by general and detailed otolaryngology examination. The nose examination included anterior rhinoscopy using Thudicum or Killian's speculum and posterior rhinoscopy using St. Clair Thompson's post nasal mirror. Complete blood examination was also carried out in order to rule out systemic causes and coagulopathies. Nasal endoscopy was performed if no definite cause was detected by the above mentioned clinical examination to account for epistaxis.

Rigid 4mm nasal endoscope, 0 and 30 degree were used for the procedure. First, the nasal cavity was packed with patties soaked in 4% xylocaine and xylometazoline nasal drops. On removal of the nasal patties after 10 minutes, endoscopy was performed by three passes. First pass was done to examine inferior meatus and nasopharynx. Second pass was carried out to examine sphenoethmoidal recess. Middle meatus was examined in detail during the third pass. Bleeding points seen were cauterized during the procedure. Based on the endoscopic results, appropriate treatment was planned. Regular follow-up was done for all patients.

## RESULTS

A total of 50 patients with epistaxis were studied during the period. Total population included 33 (66%) males and 17 (34%) females (Figure-1). The youngest was an 11 year old boy and oldest was a 58 year old male. Maximum number of patients (46%) was in the age group of 21-30 years (Table -1).

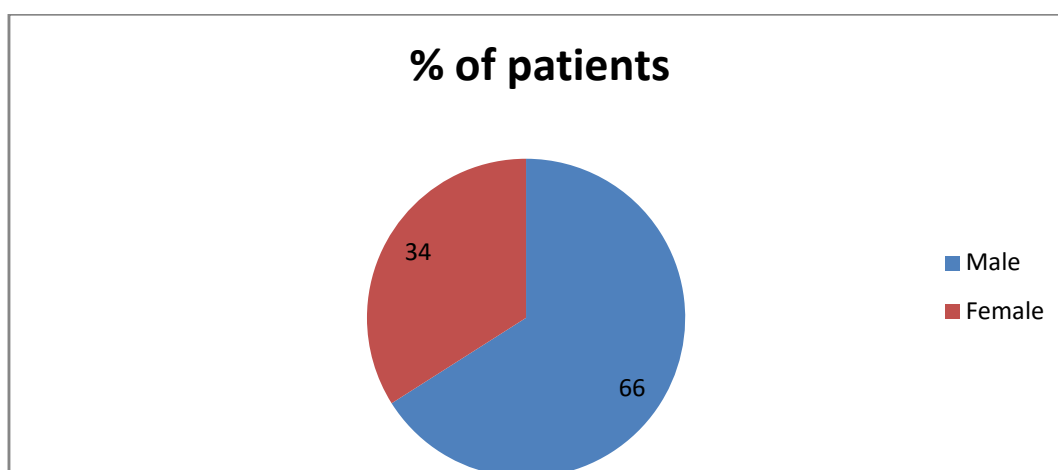


Figure-1: Patient distribution according to gender

Table-1: Patient distribution according to age.

Age Range (Years)	11-20	21-30	31-40	41-50	51-60
Number of Patients	10	23	9	2	6
Percentage	20%	46%	18%	4%	12%

**Endoscopic findings and treatment-** Tables 2 and 3 show the endoscopic findings and treatment methods, respectively. In our study, 12 (24 %) patients were found to have posterior deviation of nasal septum with spur. Septal correction with removal of spur was done for them. Infected polyp was seen in 5 (10%) of the cases. They were first treated with antibiotics and nasal decongestants. After the infection subsided, endoscopic polypectomy was done for three patients. The remaining two patients, who were not willing for surgery, were started on topical steroid nasal sprays twice daily for four months. In 4 (8%) patients, we observed crusts in the nasal septum and floor of the nasal cavity. Two among them were ironsmiths and one was employed in a dry dusty place outside India. Crusts were removed by nasal douching and topical antibiotic steroid ointment was applied. Allergic rhinitis along with deviated nasal septum was found in 4 (8%) patients. Septoplasty followed by conservative treatment for allergic rhinitis was given for 2 patients, while the remaining two without significant septal deviation were treated conservatively without surgery. The conservative treatment for allergic rhinitis included antihistamines and steroid nasal sprays.

Rhinosporidial mass in the nasal cavity was seen in 5 (10%) cases. Excision and cauterization of base was done for all patients. Only 2 (4%) patients had sinusitis with deviated nasal septum. After giving antibiotics, preferably Amoxicillin, and nasal decongestants for sinusitis, septal correction was done for them. Congested adenoids were found in 4 (8%) cases. All these patients were in the age group 11-20 years. These patients developed epistaxis after an upper respiratory infection. For them, steroid nasal spray was started after a course of antibiotics. The spray was continued for four months.

In 6 (12%) patients, we found bleeding points on the nasal septum on endoscopic examination, which were cauterized. Haemangioma of posterior part of the nasal septum was detected in 1 (2%) patient. Excision and cauterization was done for it. In 2 (4%) patients, small proliferative growth was seen in the lateral nasopharyngeal wall. In view of the suspicion of malignancy, we referred these 2 patients to higher centre for further evaluation and treatment. One (2%) patient had posterior septal perforation with an irregular ulcer at the margin from which endoscopic biopsy was taken. Histopathology report came as poorly differentiated carcinoma and hence the patient was referred to Regional Cancer Centre, Trivandrum. In one case, we noticed a bulge in the left lateral nasal wall at the region of middle meatus. CT scan of nose and paranasal sinuses showed suspected malignancy of maxilla. Therefore, we referred the patient to a higher centre. In 3 (6%) cases, no significant local cause was detected for epistaxis.

**Table-2: Endoscopic findings.**

Diagnosis	Number of Cases	Percentage
Posterior septal deviation with spur	12	24%
Bleeding points nasal septum	6	12%
Infected polyp	5	10%
Rhinosporidiosis	5	10%
Crusts in the nasal cavity	4	8%
Deviated Nasal Septum with allergic rhinitis	4	8%
Congested adenoids	4	8%
No significant cause	3	6%
Deviated Nasal Septum with sinusitis	2	4%
Nasopharyngeal mass	2	4%
Haemangioma Nasal septum	1	2%
Bulge in the lateral nasal wall	1	2%
Posterior septal perforation with ulcer	1	2%
<b>Total</b>	<b>50</b>	<b>100%</b>

**Table-3: Treatment methods for patients with epistaxis.**

Treatment	Number	Percentage
Septal correction	12	24%
Endoscopic excision and cauterization	6	12%
Antibiotics followed by steroid nasal spray	6	12%
Endoscopic cauterization	6	12%
Nasal douching and topical antibiotics	4	8%
Endoscopic polypectomy and biopsy	3	6%
Referred to higher centre	3	6%
Septal correction and Treatment of allergy	2	4%
Conservative Treatment for allergy only	2	4%
Antibiotics followed by septal correction	2	4%
Endoscopic biopsy	1	2%
No treatment given	3	6%
<b>Total</b>	<b>50</b>	<b>100%</b>

Patients were on regular follow-up for four months. One patient who underwent endoscopic cauterization of bleeding points had recurrent nasal bleeding. For this patient, repeat cauterization was done and the patient was asymptomatic after that. One patient had polypoidal changes in the middle meatus after endoscopic polypectomy. He was managed with nasal sprays. There were no further episodes of epistaxis for the rest of the patients.

## DISCUSSION

Epistaxis is one of the most common emergencies in otolaryngology department. Nasal endoscopy improved the precision in the diagnosis and treatment of epistaxis [7, 9]. It allows the evaluation of nasal passage with a high quality magnified view. The use of endoscope for the treatment of epistaxis reduces the morbidity due to nasal packing and other external surgical procedures [9].

In our study, males were affected more than females. Similar findings are seen in other studies as well [4,10]. In our study of 50 patients between 11-60 years, epistaxis was found to be more common in the age group 21-30 years (46%), where as in the study by Safaya et al [5] in patients above 20 years, most cases were in the above 50 age group (30%). We found posterior septal deviation with spur as the most common cause (24%) of epistaxis. This is in correlation with the study by Safaya et al [5] on 60 patients. In their study, the most common cause was posterior septal deviation with ulcer (23.3%). This is contradictory to the data available in some other literature [4,6]. Bleeding from the crevices of the lateral nasal wall was the commonest etiology for epistaxis in the study conducted by Mahesh Babu et al [4] on 50 patients (24%) and by Kumar et al [6] on 60 patients (28%). For them posterior septal deviation was the second common cause for epistaxis. In our study, septal correction was the treatment given for 24% of patients with posterior

deviation and spur. The spur was difficult to be visualized by anterior rhinoscopy. Infected polyp accounted for 10% cases. In other studies also infected polyp was found to be a cause of epistaxis [4-6]. Hypertrophied turbinates and oedematous nasal mucosa obscured the view of the polyp during anterior rhinoscopy, which we could clearly visualize by nasal endoscopy after nasal decongestion. All patients with rhinosporidiosis in our study were males. Most patients had the habit of swimming in ponds. In 8% of cases, no causes other than congested adenoids were found on endoscopy. All these patients were in the age group of 11-20 years and were having minimal epistaxis. They had history of upper respiratory infection prior to epistaxis. Similar results were seen in other studies also [4, 6]. Endoscopic cauterization of bleeding points was done in 12% cases. According to a study conducted by Elwany S et al [10], endonasal surgical management of epistaxis is superior to posterior nasal packing and angiography or embolisation.

Nasal endoscopy helped us to find other diseases like haemangioma nasal septum and malignancy nasal septum. In the retrospective study by Parajuli R [11] on 84 patients, the most common cause was found to be idiopathic (38.09%), followed by hypertension (27.38%). Our study analyzed only the local causes of epistaxis.

## CONCLUSION

Epistaxis is an emergency condition. All age groups are affected with a male preponderance. Local causes of epistaxis which are missed by anterior and posterior rhinoscopy can be easily detected by nasal endoscopy. In our study, posterior septal deviation with spur was the most common aetiological factor. Some other causes included infected polyp, rhinosporidiosis, bleeding points on the septum, congested adenoids and nasopharyngeal mass. Septal haemangioma and malignancy of nasal septum also presented as epistaxis. Nasal endoscopy helped in the diagnosis and early treatment planning in these patients. Endoscopic cauterization of bleeding points in posterior epistaxis was always better than post nasal packing and other invasive procedures, as it reduces the morbidity. If the local causes of epistaxis are identified and treated, either by surgical or non surgical methods, the recurrences are less.

## Acknowledgements

1. Dr. Joy Philip, Principal, SUT Academy of Medical Sciences, Trivandrum.
2. Dr. Sulekha B., Professor and Head, Department of Bio-chemistry, SUT Academy of Medical Sciences, Trivandrum.
3. Dr. Sindhu B. S., Assistant Professor, Department of ENT, Government Medical College, Kottayam.

**Ethical Committee Approval:** Obtained from the institutional ethical committee.

**Funding:** Nil, **Conflict of interest:** None initiated.

**Permission from IRB:** Yes

## REFERENCES

1. Hazarika MP, Nayak DR: Textbook of Ear, Nose, Throat and Head and Neck Surgery: New Delhi: CBS Publishers: 2012
2. Dhingra PL, Dhingra S: Diseases of Ear, Nose and Throat: New Delhi: Elsevier: 6<sup>th</sup> Edition: 2014.
3. Almeida GS, Diógenes CA, Pinheiro SD. Nasal endoscopy and localization of the bleeding source in epistaxis: last decade's revolution. *Braz J Otorhinolaryngol.* 2005 Mar-Apr; 71(2):146-8. Epub 2005 Aug 2.
4. Mahesh Babu M, Gowda B, Satish HS. Role of Rigid Nasal Endoscopy in the Diagnosis and Management of Epistaxis. *IOSR Journal of Dental and Medical Sciences*, 2014; 13 (3): 40-45. ICID: 1113213.
5. Safaya A, Venkatachalam VP, Chaudhary N. Nasal Endoscopy-Evaluation in Epistaxis. *Indian Journal of Otolaryngology and Head and Neck Surgery.* 2000 Apr; 52(2): 133–136. PubMed PMC3451285.
6. Kumar MVV, Prasad KUR, Gowda PRB. Rigid Nasal Endoscopy in the Diagnosis and Treatment of Epistaxis. *J Clin Diagn Res.* 2013 May; 7(5): 831–833. doi: 10.7860/JCDR/2013/4421.2995. Epub 2013 May 1.
7. Chhapola S, Matta I, Marker P. Comparison of Blind Nasal Packing vs Endoscopic Control of Epistaxis in an Emergency Setting. *International Journal of Head and Neck Surgery.* 2011 May-Aug; 2(2): 79-82.
8. Shelkar R, Vedi J, Ekhar V, Dasgupta KS, Lanjewar K. Role of Nasal Endoscopy in Sinonasal Diseases. *International Journal of Scientific study.* 2014;2(1):6-10.
9. Stankiewicz JA. Nasal endoscopy and control of epistaxis. *Current Opinion in Otolaryngol Head Neck Surgery.* 2004 Feb; 12(1): 43–45. PubMed 14712120.
10. Elwany S, Hesham AF. Endoscopic Control of Posterior Epistaxis. *The Journal of Laryngology and Otology.* 1996 May; 110: 432–34. DOI: <http://dx.doi.org/10.1017/S0022215100133900>.
11. Parajuli R. Evaluation of Etiology and Treatment Methods for Epistaxis: A Review at a Tertiary Care Hospital in Central Nepal. *International Journal of Otolaryngology.* 2015; Volume 2015:1-6. <http://dx.doi.org/10.1155/2015/283854>.

## How to cite this article?

Swapna U.P., Simla S.R., Anjali R., Salil kumar K. Endoscopic evaluation and treatment of epistaxis – A prospective study. *Int J Med Res Rev* 2016;4 (6):971-975.doi: 10.17511/ijmrr.2016.i06.18.