

Utility of MRI in uterine and adnexal lesions

Kochiyil J¹, Vernekar J²

¹Dr. JyotsnaKochiyil, Radiodiagnosis, ²Dr. Jeevan Vernekar, Professor and Head Department of Radio diagnosis, Goa Medical College, Goa, India

Address for correspondence: Dr JyotsnaKochiyil, Email: justjo.20@gmail.com

Abstract

Objective: To ascertain the role of MRI as a problem solving modality in characterising indeterminate uterine and adnexal masses from USG. **Methods:** A prospective study was conducted with 100 female patients with pelvic pathologies who underwent an ultrasound examination and proved to be diagnostic dilemmas. These patients were further investigated with an MRI of the pelvis without contrast. Routine sequences were performed in all patients including T1Wi, T2Wi and GRE. **Results:** There were 70 uterine lesions (fibroids -39, adenomyosis -14, Müllerian anomalies - 4, bulkiness of uterus -8, low lying placenta antenatal scan -2) and 30 adnexal lesions (malignant ovarian cysts -10, dermoid cyst - 6, chocolate cyst -8, tubovarian masses - 6, chronic torsion -1, chronic ectopic - 1, peritoneal inclusion cyst -1). The diagnosis made after the MRI scan was compared to the working diagnosis made from USG and these were separately compared with the HPR diagnoses in 53 patients who underwent surgery. The remaining 43 patients who were treated conservatively the MRI diagnoses were compared with the working USG diagnoses. The statistical data was analysed by contingency coefficient, CC, method (variant of Chi square method). The CC for USG diagnoses and postoperative diagnoses was statistically significant. The CC for MRI diagnoses and postoperative diagnoses was 0.684 at a p value of 0.013. **Conclusions:** The analysis of data from the study indicates a strong association between the MRI diagnoses and the postoperative diagnoses, more so than the USG diagnoses and the postoperative diagnoses. There is more variability between the USG diagnoses and the postoperative diagnoses by comparison.

Keywords: Diagnostic modality, Female pelvic pathologies, MRI, Problem solving, Ultrasonography

Introduction

Female pelvic pathologies have been common cause of morbidity in the population worldwide. Large screening studies show that majority of these lesions are benign even though the malignant ones are significant cause of mortality. As such, it becomes important to ascertain an accurate diagnosis in these cases with imaging so that appropriate and timely interventions can be made.

USG has been the mainstay of imaging in female pelvic pathologies for many decades. The advent of high resolution trans vaginal USG has carried this further providing greater diagnostic accuracy. However, despite its many advantages this modality puts physicians in a diagnostic dilemma more often than thought. In these situations, the relatively new entrant in the diagnostic

armour, MRI comes to the rescue. In addition to its high contrast resolution and multi planar imaging capability MRI gives us the edge in imaging by being able to differentiate between the types of tissue, their malignant potential and other characteristics based on their signal intensity and come to a diagnostic conclusion prior to surgery. Also MRI is the choice investigation after USG in specific groups of the population such as pregnant women [1] and young children [2] who cannot undergo a CT scan due to risk of ionising radiation. But the real gap comes because physicians and general radiologists cannot decide if and when it is appropriate to refer a patient for MRI scanning after USG [3]. Some of the earlier studies conducted in this regard include correlation of pelvic magnetic resonance imaging diagnosis with pathology for indeterminate adnexal masses by Haggerty A F et al [4] which compared the accuracy of MRI with final pathological diagnoses in

Manuscript received 25th March 2016
Reviewed: 04th April 2016
Author Corrected: 14th April 2016
Accepted for Publication 28th April 2016

indeterminate adnexal masses, Characterization of Adnexal Mass Lesions on MR Imaging by S.A. Soahib et al [5] which brought forward the accuracy of MR imaging in detection and characterisation of adnexal mass lesions .A two-stage imaging protocol for evaluating women presenting with acute pelvic pain by Amal Amin Abu El Maati et al[6] which showed that sequential imaging with USG followed by MRI for

cases with inconclusive USG findings optimises the diagnostic accuracy.

In this study the specific objectives are to use MRI imaging as problem solving tool in indeterminate uterine and adnexal lesions from USG and to characterise the uterine and adnexal lesions according to their MRI characteristics.

Materials and Methods

The study was conducted from July 2012 to July 2014 .All diagnostically difficult female pelvic pathologies on USG during this period were included. Previously diagnosed cases by CT/MRI, known cases of malignancy from HPR reports were excluded from the study. First a working diagnosis was made from the USG examination. This was followed by the MRI scan of the pelvis without injection of contrast. Informed consent for an MRI scan without contrast was taken from all patients. The MRI scans were performed on 1.5 T Magnetom AVANTO from SIEMENS with software version SYNGO B13.A pelvic phased array coil was used in all patients and the following sequences were obtained routinely in all patients.

Table-1: MRI protocol for the study

Sequence	TR(ms)	TE(ms)	Slice thickness(mm)	FOV(mm)	Phase coding direction	Phase over sampling(%)	Distance factor (%)	Averages	Voxel (mm)	Flip angle (°)
T2coronal trufi(bh)	4.13	2.07	5	400	R>>L	23	50	1	2.1X1.6 X5.0	70
T2 trufi transverse(bh)	4.35	2.18	4	325	A>>P	29	60	1	1.7X1.3 X4.0	70
T1 tse sagittal	627	11	4	230	A>>P	40	40	2	1.0X0.7 X0.4	150
T2 tse sagittal	5070	101	2	230	R>>L	80	40	2	1.1X0.9 X2.0	150
T2 tse transverse	6050	96	4	230	A>>P	40	30	1	1.1X0.9 X4.0	150
T2 tse coronal	3000	96	4	100	R>>L	50	10	1	1.2X1.0 X4.0	150
T2 se transverse fat sat	5420	96	4	230	A>>P	40	30	1	1.1X0.9 X4.0	150
Transverse hemoflash	1250	20.6	5	230	A>>P	67	0	1	1.2X0.9 X5.0	20
ep2d diff(B50,400,800)	4300	85	4.5	350	A>>P	0	30	4	1.9X1.9 X4.5	
T1 fl2dtrambh	122	4.76	6	350	A>>P	0	20	1	2.0X1.4 X0.6	70
T1 fl2d oppphtrambh	100	2.38	6	350	A>>P	0	30	1	2.0X1.4 X0.6	70

The signal intensity characteristics of the lesions were studied on T1Wi and T2Wi first followed by fat saturation, hemoflash, DWi at B values of 50,400 and 800, in phase and opposed phase characteristics. Detailed assessment of the sequences was performed and the final diagnosis made. The diagnosis made after the MRI scan was compared to the working diagnosis made from USG and these were separately compared with the HPR diagnoses in 53 patients who underwent surgery. The remaining 43 patients who were treated conservatively the MRI diagnoses were compared with the working USG diagnoses. The statistical data was analysed by contingency coefficient, CC, method (variant of Chi square method).

Results

In the one hundred cases studied, analysis of age distribution of the patients show that majority of the patients with indeterminate pelvic pathologies were in the age group of 31 – 40 years(46). Most of the patients were para 2 on assessment of the parity status (39). From analysis of the chief complaints that the patient presented with, it was found that majority (52) had abdominal pain as a symptom either alone or along with other symptoms such as menorrhagia.

Assessing the pathologies, it was found that most of the indeterminate cases were primarily uterine in origin (70) compared to adnexal lesions (30). Analysis of the difficult uterine pathologies on USG revealed fibroids (39) followed by adenomyosis (14) predominantly. Other cases include bulkiness of the uterus(8), Mullerian anomalies (4) and low lying placenta in antenatal scan (2).

Table 2: Distribution of uterine lesions

Uterine lesion	Number of cases
Fibroid	39
Adenomyosis	14
Uterine anomalies	4
Bulky uterus	8
Antenatal scans for low lying placenta	2

Analysis of the indeterminate adnexal masses revealed most of them to be malignant ovarian cysts (10) followed by chocolate cyst (8) and dermoid cyst (6). Other lesions include tuboovarian masses (6), chronic torsion (1), chronic ectopic (1) and peritoneal inclusion cyst (1).

Table 3: Distribution of adnexal lesions

Adnexal pathology	Number of cases
Neoplastic ovarian cyst	10
Dermoid cyst	6
Chocolate cyst	8
Tuboovarian mass	6
Chronic torsion	1
Chronic ectopic	1
Peritoneal inclusion cyst	1

The assessment of signal intensity characters on MRI shows that most of the indeterminate adnexal masses are complex cysts (26) compared to solid lesions(7). Analysis of the complex cysts revealed septations in most (16) and hemorrhage (9) compared to mural nodules (2).

Table 4: Characterization of cystic adnexal lesions

Type of lesion	Number of cases
Cyst with septae	16
Cyst with solid nodule	2
Cyst with hemorrhage	9

Comparison of the working USG diagnosis with post operative diagnoses in the 53 patients who underwent surgery shows that USG diagnoses agreed with post operative diagnoses in 30 cases with incorrect diagnoses in 11 cases and inconclusive diagnoses in 12 patients.

Table 5: Comparison of the USG diagnosis with post operative diagnosis

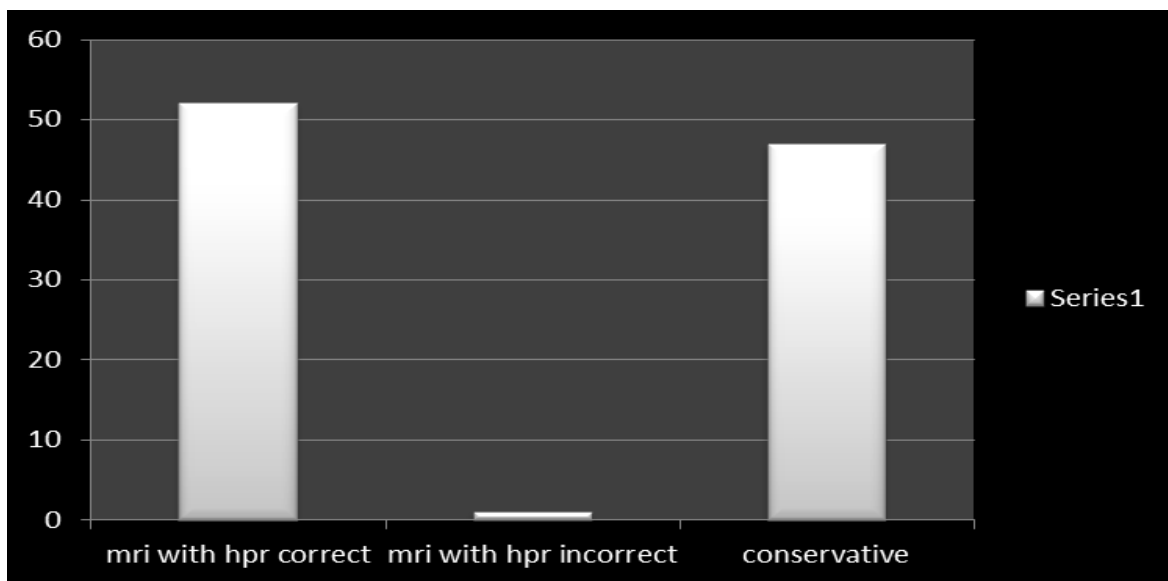
USG with HPR correct	30
USG with HPR incorrect	11
Patients managed conservatively	47
No conclusive diagnosis on USG	12

On comparing the MRI diagnoses with the post operative diagnoses it was found that they agreed in majority of cases (51) and differed only in two cases.

Table 6: Comparison of the diagnosis by MRI with post operative diagnosis

MRI and post op diagnosis same	51
MRI and post op diagnosis differ	2
Patients managed conservatively	47

Fig -1: Bar graph showing correlation of MRI diagnosis with HPR diagnosis



Data analysis was done using SPSS software. The contingency coefficient method (variant of chi square method) was used. The CC for USG diagnoses and postoperative diagnoses was 0.775 at a p value of 0.001. The CC for MRI diagnoses and postoperative diagnoses was 0.684 at a p value of 0.013.

This indicates the relevance of both the tests. In our study, we found that of 53 patients who underwent surgery MRI diagnosis agreed with post operative diagnosis in 51 patients; whereas USG diagnoses agreed in only 30 patients. Hence it was concluded that MRI proves to be a better modality in comparison to USG on qualitative assessment.

Discussion

In this study of 100 patients with pelvic pathologies which were indeterminate on USG, analysis of the data shows some salient features. In the study group most of the cases were in the 31- 40 years age group. This can be due to the fact that lesions in the younger and older age groups are diagnostically easier as most will be

congenital or infectious in the young and neoplastic more likely malignant in the aged. The difficult group is the reproductive age group in whom the common pathologies present with symptoms like acute abdominal pain which warrants further investigation [7]

The parity assessment shows that most of the patients were para 2, followed by nullipara and para 1. This might be due to the fact that nulliparity being a risk factor for estrogen dependent lesions such as fibroids and certain ovarian malignancies; these will be more confidently diagnosed with USG in such patients. Nulliparity is a risk factor in patients presenting with dysmenorrhoea according to studies [8]. Likewise, adenomyosis is more common in a multiparous woman that it makes the diagnosis on USG easier. It is when the patient does not have such risk factors that the diagnosis becomes more difficult from USG alone.

Abdominal pain was the most common symptom in this study, suggesting that even with subtle symptoms like non specific abdominal pain, patient may harbour a diagnostically challenging lesion highlighting that sufficient time should be given for each patient and the difficult cases have to be further investigated.

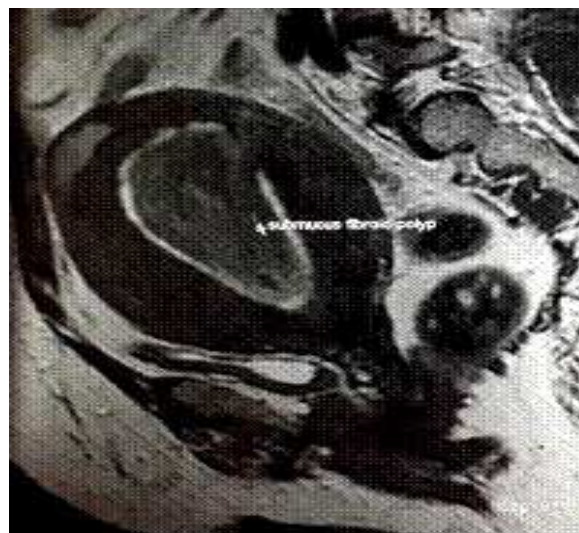From the distribution of difficult pelvic pathologies into uterine and adnexal lesions, majority were found to be uterine in origin. This is due to the higher prevalence of uterine pathologies such as fibroids (20 – 40 %) in the reproductive age group [9] compared to adnexal lesions.

Among the 100 patients studied, approximately 40 % of the lesions turned out to be cases of fibroid. Of these 26 were already diagnosed on USG however, after MRI multiple other fibroids could be picked which were not seen on USG. MRI is the most sensitive modality (88 – 93 %) in the diagnosis of uterine fibroids [10] especially the smaller ones [11].

Regarding the distribution of fibroids, majority of the fibroids detected were intramural (33). Nine cases of submucosal fibroids, of which 5 were submucosal fibroid polyps was also detected on MRI. Among the submucosal fibroids only 2 cases were suspected on USG.

Two cases of subserosal (broad ligament) fibroids were also picked up on MRI scan whereas on the USG diagnosis of adnexal mass was suggested. A suspected cervical fibroid on USG turned out to be a supracervical intramural fibroid on MRI. Another suspected case of endometrial polyp on USG turned out to be a submucous fibroid polyp on MRI scan. Submucosal, intramural and subserosal fibroids are easily differentiated on MRI as also are fibroids in unusual locations such as cervix which is supported by earlier studies [11].

Fig -2. Submucous fibroid polyp detected on MRI



MRI was 100 % sensitive in diagnosing fibroids as compared to USG. Fibroid mapping could be more accurately done, especially submucous fibroids were better identified on MRI and more fibroids could be identified in the MRI scan than on USG.

In a study done by Eric .D. Levens et al [12] comparing TVS and MRI, they found that MRI has superior sensitivity in detecting fibroid tumors. Submucous fibroid tumors were best identified with MRI (100% sensitivity; 91% specificity). MRI has excellent reproducibility, whereas TVS demonstrated lower reproducibility, and substantial disparities were found when results were obtained by different observers using TVS.

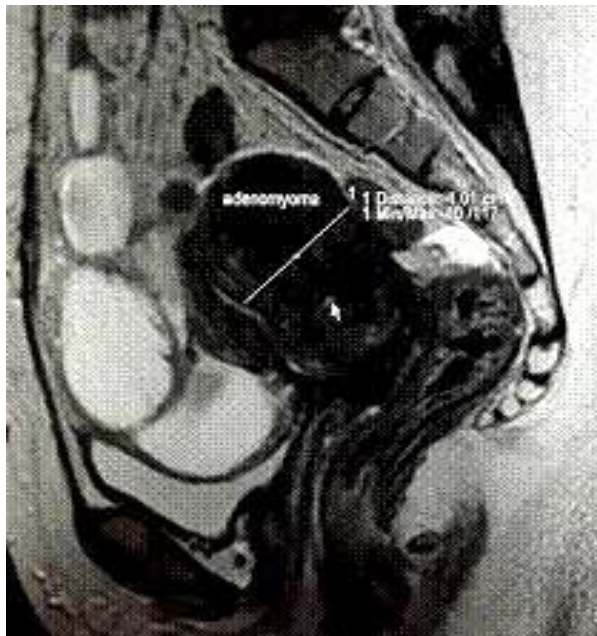
The next most common uterine pathology that was found was adenomyosis. Among the 11 cases of adenomyosis diagnosed on MRI, 7 were reported as bulky uterus on USG. On MRI scan the characteristic junctional zone widening and T2Wi hyperintense branching myometrial cysts could be clearly visualized, clinching the diagnosis.

Three suspected cases of heterogenous myometrium in a bulky uterus on USG were confirmed by the MRI study. Another case was incidentally picked when the MRI was done for evaluation of fibroids. Two cases of focal adenomyomas could also be well characterized from MRI study.

Studies show that MRI has 77.5 % sensitivity and 92.5 % specificity in the diagnosis of adenomyosis uteri [13]. In our study, eight among the diagnosed cases of

adenomyosis were operated and the post operative diagnoses were conforming to MRI findings.

Fig 3: Focal adenomyosis along the posterior uterine wall detected on MRI,T2Wi sagittal sequence

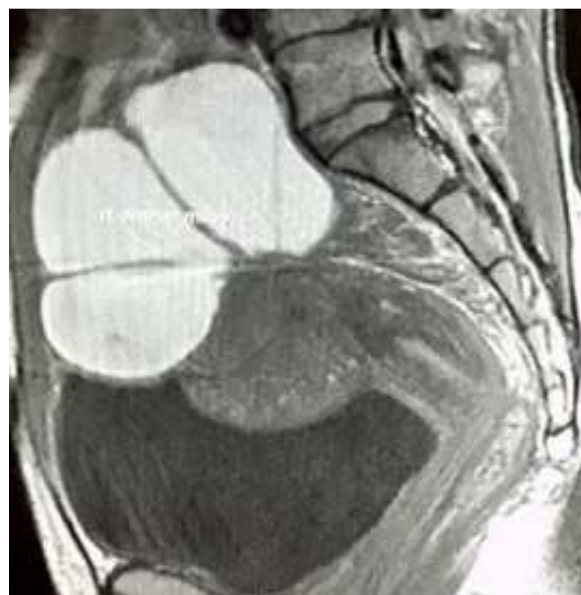

A sonographically indeterminate adnexal mass is defined as (a) one that has complexity but that, after thorough interrogation including Doppler assessment, cannot be confidently placed into either the benign or malignant category or (b) one for which the site of origin, from the ovary, uterus, or another pelvic structure, remains to be established. Indeterminate adnexal masses are within the “gray area” between complex benign disease and early malignancy [14].

Of the 33 difficult adnexal lesions on USG, both neoplastic and benign lesions were detected on MRI. The most common were benign ovarian lesions. Among the benign adnexal pathologies chocolate cysts(9), tubo-ovarian mass (5)in pelvic inflammatory disease predominated; while other cases like, hematosalpinx in ectopic pregnancy (1), chronic ovarian torsion(2), and peritoneal inclusion cyst(1) forming the rest.

The endometriomas were difficult to diagnose on USG because some of them were large and septated simulating neoplasms. In the cases of endometriosis in our study, MRI was helpful in characterization of the cysts, delineating other endometriotic implants and also detecting endometriomas in the other ovary.

Fig-4.Endometriotic cysts with hemorrhage on MRI, T1Wi sagittal sequence



Studies have shown that MRI can be very useful in patients in whom ultrasound findings are equivalent and in carefully selected high risk population. It is especially beneficial in identifying endometriomas, adhesions, superficial peritoneal implants and extraperitoneal lesions, particularly those in the recto vaginal pouch and uterosacral ligaments as well as in solid endometriotic nodules.

The signal intensity of MRI depends on the contents of the endometrial implants. The contents of these implants mainly include the proteins and degraded blood products, the ratio of which varies according to the stage of the haemorrhage and thus the variation in the signal intensity can be noted on MR images. The acute haemorrhage may give hypointense (dark) signal on the T1 and T2 weighted images. In contrast the lesions containing degraded blood products like methemoglobin, proteins and iron may be seen as hyperintense (bright) on T1 and hypointense (dark) on T2 weighted images. Multiple high signal lesions, usually in the ovaries, on T1-weighted images, also are highly suggestive of endometriosis.

The findings in our study were comparable to other studies, confirming the superiority of MRI over USG in pelvic endometriosis [15].

In the case of the 5tubovarian masses in our study, associated with pelvic inflammatory disease, presence of more lesions and extent of the disease was better characterized on MRI than on USG. Bilateralism was

detected in many cases only on the subsequent MRI scan. MRI also helped in detecting tubovarian abscesses by showing diffusion restriction in such cases. Timely management with broad spectrum antibiotic coverage was possible in many of these after the MRI scan, alleviating the need for unnecessary interventions

In cases of PID, presence of tubovarian abscess could be made out on MRI by demonstrating hypointensity on T1Wi, heterogeneous intensity on T2Wi and showing diffusion restriction.

Studies have shown that the sensitivity of MRI in the diagnosis of PID was found to be 95%, with a specificity of 89%, and overall accuracy was 93% [16] compared to the corresponding values of 81%, 78%, and 80% for TVS respectively. MRI is more accurate than transvaginal US and provides information about the differential diagnosis of PID, and as such its use may also reduce the need for diagnostic laparoscopy. MRI can be useful in PID especially when sonography is inconclusive or non-diagnostic.

Two cases of chronic ovarian torsion could be diagnosed conclusively on MRI which showed unilateral enlarged non enhancing ovary located medially with twisting of its pedicle showing whirlpool sign. The diagnostic dilemma on USG which was showing flow within the ovary could be satisfactorily resolved after MRI by demonstrating the torqued pedicle.

Sagittal MR imaging may be more helpful in detecting a thickened tube, which may be visualized as a tubular protrusion on the twisted side. Additional imaging findings that can suggest hemorrhagic infarction following adnexal torsion include eccentric smooth wall thickening exceeding 10 mm in a cystic ovarian mass converging on the thickened tube, lack of contrast enhancement of the internal solid component or the thickened wall of a twisted ovarian mass, hemorrhage within the tube or twisted ovarian mass, and hemoperitoneum [17].

In another case of heterogeneous adnexal mass on USG, patient presenting with acute pelvic pain, was diagnosed to have chronic ectopic gestation after the MRI scan and timely intervention was done in this patient who had equivocal clinical and lab parameters.

The rest of the indeterminate adnexal lesions were neoplastic (15). This includes serous cystadenoma (5) mucinous cystadenoma (3), dermoids (5) and mixed

germ cell tumors (1) in the operated cases. The rest were not operated during the study period.

Of the neoplastic lesions majority were diagnosed as large cystic lesion with thick wall, multiple thick septae and mural nodules on USG which turned out to be serous and mucinous neoplasms of the ovary. The ovary of origin could not be ascertained on the USG in most of these and MRI helped in these cases by showing a normal ovary on the other side. Also other associated features such as ascites and enlarged lymph nodes could be better seen on the MRI scan.

On USG, adnexal masses which were described as heterogenous with echogenic component turned out to be dermoid, which on MRI scan show edhyperintensity on T1Wi and T2Wi showing suppression on fat suppressed sequences.

Studies show that the sensitivity of MRI for identifying malignancy (n = 5) was 100% and its specificity for benignity (n = 90) was 94%. Excellent agreement was seen between MRI and the final diagnosis for determining the origin ($\kappa = 0.93$), tissue content ($\kappa = 0.98$), and tissue characteristics ($\kappa = 0.91$) of a mass. Sonography had poor agreement with the final diagnosis for the origin ($\kappa = 0.19$) and tissue content ($\kappa = 0.33$) of a mass. The main reasons for indeterminate sonographic diagnoses were the inability to determine origin because of location and large mass size and the appearances of purely solid or complex cystic masses [18].

Among the other diagnostic difficulties faced on USG include cases of Müllerian duct anomalies (MDA). There were four cases of MDA in which the uterine configuration and presence of ovaries could be clearly made out on the MRI, when it was difficult to visualize on USG because of bowel loops and inability to do transvaginal USG in these patients.

Currently, however, MR imaging remains the preferred MDA imaging method, as it exquisitely details both the uterine cavity and external contours and has shown excellent agreement with clinical MDA subtype diagnosis [19]. Studies have proven that Magnetic resonance imaging is safe and gives a diagnostic accuracy close to 100%. Magnetic resonance imaging demonstrated 100% sensitivity and specificity compared to 67% sensitivity and 100% specificity of transvaginal sonography for unicornuate or bicornuate uteri (anomalies requiring surgery). For non-surgical

uterine anomalies, both techniques had 100% sensitivity and specificity.

Pellerito *et al*[20] also noted that magnetic resonance imaging had the further advantage of detecting other incidental abnormalities, including a dermoid and submucosal leiomyoma, not found on ultrasound.

Four antenatal MRI scans were included in this study. They were done as the lower margin of the placenta, its interface with the bladder was dubious on USG. On MRI the loss of the T2Wi hypointense wall of urinary bladder adjacent to the placenta, with placental tissue seen through the bladder wall, helped in the conclusive diagnosis of placenta percreta. Another case of a term ectopic abdominal pregnancy with uterine rupture was also diagnosed on MRI scan after the USG was done. The obstetricians could be forewarned in the above two situations so they could anticipate the complications during the surgery and delivery could be conducted smoothly.

Currently, MRI is being increasingly used as a correlative imaging modality to USG in antenatal patients because of the lack of ionising radiation and better spatial resolution. In those patients who are obese or have oligo-hydramnios, MRI has obvious advantage over USG.

Conclusion

From this study done on 100 female patients with indeterminate pelvic pathologies on USG, who were further assessed by MRI to form a conclusive diagnosis, we find that MRI is an effective method of detecting and characterizing adnexal and uterine lesions. Even though, ultrasound remains the first line of imaging for female pelvis, with high diagnostic accuracy rates for uterine and ovarian abnormalities, MRI should be considered for the evaluation of adnexal pathology when sonographic characteristics are not definitive to determine whether an adnexal mass is ovarian in origin and to determine the likelihood of malignancy. Its multiplanar imaging ability has a significant advantage to detect lesions, to locate lesion and identify solid from cystic nature of lesion and there by aid in characterization of lesion.

To conclude, MRI provides far superior information regarding uterine and adnexal masses as well as surrounding structures and hence has carved a niche for

being an excellent diagnostic modality, specially as a problem solving tool in various pelvic pathologies.

Acknowledgements: I wish to express my heartfelt thanks and deep gratitude to my teacher and guide Dr. Jeevan Vernekar, M.D ,D.N.B. (Professor and Head, in the Department of Radio diagnosis, Goa Medical College) for his help, guidance, advice and encouragement at every stage of this work.

I am thankful to all the other teaching and non teaching staff of the Department of Radio diagnosis and the Department of Obstetrics and Gynaecology ,Goa Medical College for their help.

I am grateful to all my patients who were a part of this study. It is their co-operation which made this study possible.

Abbreviations

CC- contingency coefficient, CT – Computerised Tomogram, HPR – Histopathological Report, MDA- Mullerian Duct Anomalies, MRI –Magnetic Resonance Imaging, TVS- Transvaginal Ultrasonogram, USG – Ultrasonography

Funding: Nil, **Conflict of interest:** None.

Permission of IRB: Yes

References

1. Beddy P, Keogan MT, Sala E, Griffin N. Magnetic resonance imaging for the evaluation of acute abdominal pain in pregnancy. *Semin Ultrasound CT MR.* 2010 Oct;31(5):433-41. doi: 10.1053/j.sult.2010.08.003.
2. Patel V S, Somers S. MR imaging of the female pelvis: current perspectives and review of genital tract congenital anomalies, and benign and malignant diseases, *Diagnostic Imaging* 1997 Oct;38(5):417-99
3. Jennifer Hubert, Diane Bergin MD. Imaging the female pelvis : when should MRI be considered? ,*Applied radiology* 2008: 37(1):9 – 24
4. Haggerty AF, Hagemann AR, Chu C, Siegelman ES, Rubin SC .Correlation of pelvic magnetic resonance imaging diagnosis with pathology for indeterminate adnexal masses, *International Journal of gynecological cancer* 2014 Sep;24(7):1215-21.
5. Sohaib SA, Sahdev A, Van Trappen P, Jacobs IJ, Reznick RH. Characterization of adnexal mass lesions

on MR imaging. *AJR Am J Roentgenol.* 2003 May;180(5):1297-304.

6. Amal Amin Abu El Maati ,Enas Abdel GhanyIbrahima, FatmaZeinhomMokhtarb .A two-stage imaging protocol for evaluating women presenting with acute pelvic pain ,The Egyptian Journal of Radiology and Nuclear Medicine 2013 Dec 44 (4): 923 – 936

7. Al-Shukri M, Mathew M, Al-Ghafri W¹, Al-Kalbani M, Al-Kharusi L, Gowri V¹. A clinicopathological study of women with adnexal masses presenting with acute symptoms. *Ann Med Health Sci Res.* 2014 Mar;4(2):286-8. doi: 10.4103/2141-9248.129067.

8. Latthe P, Mignini L, Gray R, Hills R, Khan K. Factors predisposing women to chronic pelvic pain: systematic review. *BMJ.* 2006 Apr 1;332(7544):749-55. Epub 2006 Feb 16.

9. Khan AT, Shehmar M, Gupta JK. Uterine fibroids: current perspectives. *Int J Womens Health.* 2014 Jan 29;6:95-114. doi: 10.2147/IJWH.S51083. eCollection 2014.

10. Dueholm M, Lundorf E, Hansen ES, Ledertoug S, Olesen F. Accuracy of magnetic resonance imaging and transvaginal ultrasonography in the diagnosis, mapping, and measurement of uterine myomas. *Am J Obstet Gynecol.* 2002 Mar;186(3):409-15.

11. Wilde S, Scott-Barrett S. Radiological appearances of uterine fibroids. *Indian J Radiol Imaging.* 2009 Jul-Sep;19(3):222-31. doi: 10.4103/0971-3026.54887.

12. Eric D. Levens, MD, Robert Wesley, PhD, AhalyaPremkumar, MD, Wendy Blocker, MSN, and Lynnette K. Nieman, MD. Magnetic resonance imaging and transvaginal ultrasound for determining fibroid burden: implications for clinical research ,American Journal of Obstetric Gynaecology 2009 May 200 (5) 537.

13. Bazot M, Cortez A, Darai E, Rouger J, Chopier J, Antoine JM, Uzan S. Ultrasonography compared with magnetic resonance imaging for the diagnosis of

adenomyosis: correlation with histopathology. *Hum Reprod.* 2001 Nov;16(11):2427-33.

14. Spencer JA, Ghattamaneni S. MR imaging of the sonographically indeterminate adnexal mass. *Radiology.* 2010 Sep;256(3):677-94. doi: 10.1148/radiol.10090397.

15. Noha Mohamed AbdelMaboud Ibrahim .The role of MRI in the diagnosis of endometriosis, The Egyptian Journal of Radiology and Nuclear Medicine 2012 December 43 (4) :631-36

16. aiyeoba O, Soper DE. A practical approach to the diagnosis of pelvic inflammatory disease. *Infect Dis Obstet Gynecol.* 2011;2011:753037. doi: 10.1155/2011/753037. Epub 2011 Jul 26.

17. Rha SE, Byun JY, Jung SE, Jung JI, Choi BG, Kim BS, Kim H, Lee JM. CT and MR imaging features of adnexal torsion. *Radiographics.* 2002 Mar-Apr;22(2):283-94.

18. Adusumilli S' Hussain HK, Caoili EM, Weadock WJ, Murray JP, Johnson TD, Chen Q, Desjardins B. MRI of sonographically indeterminate adnexal masses. *AJR Am J Roentgenol.* 2006 Sep;187(3):732-40.

19. Mueller GC, Hussain HK, Smith YR, Quint EH, Carlos RC, Johnson TD, DeLancey JO. Müllerian duct anomalies: comparison of MRI diagnosis and clinical diagnosis. *AJR Am J Roentgenol.* 2007 Dec;189(6):1294-302.

20. Pellerito JS, McCarthy SM, Doyle MB, Glickman MG, DeCherney AH. Diagnosis of uterine anomalies: relative accuracy of MR imaging, endovaginal sonography, and hysterosalpingography. *Radiology.* 1992 Jun;183(3):795-800.

How to cite this article?

Kochiyil J, Vernekar J. Utility of MRI in uterine and adnexal lesions: *Int J Med Res Rev* 2016;4(4):655-663.doi: 10.17511/ijmrr.2016.i04.31.