

Role of FNAC in the diagnosis of cysticercosis

Parakh R¹, Gupta S², Singh S³, Garewal J⁴, Rajput R⁵, Vashist S⁶

¹Dr Richa Parakh, Assistant Clinic, Coordinator; Pathologist, SPRIM, Singapore, ²Dr Sumit Gupta, Assistant Professor, Department of Pathology, NIMS Medical college Jaipur, ³Dr Swati Singh, Junior Resident, Department of Pathology, NIMS Medical College Jaipur, ⁴Dr Jaydeep Garewal, Junior Resident; Department of Pathology, NIMS Medical College Jaipur, ⁵Dr Rashmi Rajput, Junior Resident; Department of Pathology, NIMS Medical College Jaipur, ⁶Dr Shelly Vashist, Junior Resident; Department of Pathology, NIMS Medical College Jaipur, India

Address for Correspondence: Dr Sumit Gupta, **Email:** drsumitpatho@yahoo.com

Abstract

Background and Objectives: Cysticercosis is a common tropical disease. Human cysticercosis is caused by the dissemination of the embryo of *Taenia solium* in the intestine via the hepatoportal system to the tissues and organs of the body. The organs most commonly affected are the subcutaneous tissues, skeletal muscles, lungs, brain, eyes, liver, and occasionally the heart, thyroid, and pancreas. Fine needle aspiration cytology (FNAC) plays an important role in prompt recognition of this disease. **Aims:** To study the role of FNAC in the diagnosis of cysticercosis. **Methods:** Fifteen patients with subcutaneous and intramuscular nodules, who were clinically diagnosed as lipoma, neurofibroma, lymphadenitis, cold abscess, epidermal inclusion cyst, sebaceous cyst, fibroadenoma and cysticercosis were included in the present study. **Results:** In 4 (26.6%) cases, a definitive diagnosis of cysticercosis was obtained in the form of fragments of parasite bladder wall and, biopsy confirmed the diagnosis. In the rest 11 (73.3%) cases, larval fragments could not be identified on the aspirates and the diagnosis of parasitic inflammation was suggested on the basis of other cytomorphological findings. Follow-up biopsy confirmed the diagnosis of cysticercosis. **Conclusions:** Cysticercosis is continuing to be a major health problem in developing countries. Fine needle aspiration cytology (FNAC) is cost effective and simple procedure. The cytological diagnosis is quite straightforward in cases where the actual parasite structure is identified in the smears. However, in other cases, presence of eosinophils, histiocytes, a typical granular dirty background are the features which should always alert the pathologist to this possibility.

Key words: Cysticercosis, *Taenia Solium*, Fine needle aspiration cytology.

Introduction

Cysticercosis is a parasitic infection with the larval stage of *Taenia solium* [1-4]. *T. solium* is a zoonotic cestode which has a complex life cycle [5]. It is seen as cysts more commonly in the brain, muscle, heart and the orbit [1,6-8]. Humans harbour the tapeworm in the gut and act as the definitive host without significant symptoms [9]. The life span of adult tapeworm is few years during which they produce millions of eggs which are intermittently released in the environment with the faeces [10]–[12].

Humans and pigs acquire cysticercosis by ingesting *T. solium* eggs by the faeco-oral route [5]. After the

ingestion, embryos contained in the eggs are released, cross the intestinal mucosa and reach the circulatory system and dispersed in the body producing cysts mainly in the central nervous system (CNS) and in striated muscles [5].

Humans can acquire cysticercosis ingesting *T. solium* eggs released by them selves (auto infestation) or carrier of tapeworm in close contact or handling food preparation. [13], [14]. Neurocysticercosis (NCC) is caused by localization of cyst in the brain [5].

It is endemic in America, Africa and Asia and linked to low socioeconomic status, ignorance, absence of suitable diagnostic and management ability and poor

Manuscript received: 15th Feb 2016
Reviewed: 25th Feb 2016
Author Corrected: 3rd March 2016
Accepted for Publication: 11th March 2016

standards of hygiene [15]. In India, it is more common in northern parts.

The preoperative diagnosis of cysticercosis can be made by radiological tools and serological tests like ELIS, Radioimmunoassay, Complement Fixation test. Radiological scans though sensitive in diagnosing cysticercosis; especially when the parasite involves the nervous system are not cost effective nor provide final diagnosis. Positive serological tests are of value but possibility of false negative exists. False positivity is expected with cross reactivity or previous parasitic infestation with other helminths.

Fine needle aspiration cytology (FNAC) is now available as an important method for the diagnosis of subcutaneous cysticercosis. The histopathological examination of the excised tissue is the gold standard for the diagnosis.

The present study was done to analyse the

Results

The study included 15 patients in the age group 8–65 years. Among 15 patients, 6 were females and 9 were males. Out of all patients, only two complaint of multiple nodules while rest presented with single, slow growing, painless, slow-growing nodule of variable sizes. 4 cases presented with neck swelling, 5 with arm swelling and 3 with abdominal wall swelling, 1 with swelling axilla, 1 with swelling cheek and 1 with swelling breast (Table 1). On clinical examination, most of lesions were nodular, non tender and soft to firm in consistency.

Provisional clinical diagnosis of Cysticercosis was made in only 2 cases, while the majority were clinically misdiagnosed as lipoma, neurofibroma, reactive lymphadenitis, tuberculous lymphadenitis, sebaceous cyst, fibroadenoma and benign tumour (Table 1). The aspirated material consisted of few drops to 4 mL fluid of variable consistency including clear fluid with or without granular deposit in 8 cases, purulent fluid in 5 cases, and blood-mixed fluid in 2 cases. No post procedure complication were observed.

In 4 cases, a definite evidence of cysticercosis was observed. The evidence on cytology was bladder wall fragments of cysticercus although the cytomorphology was not exactly the same in all cases (Figure 1-A). None of them showed hooklets or scolex. Follow-up biopsy confirmed the diagnosis (Figure 2). All these cases showed varying proportion of inflammation with or without granuloma or giant cells.

In the rest 11 cases, the cytological findings were in favor of a parasitic cyst; however, no parasite could be seen. None of these cases showed hooklets or scolex on cytology. The cytology of these cases revealed mixed inflammatory infiltrate, macrophages, multinucleated giant cells, and non caseating epithelioid granuloma in a dirty granular background (Figure 1-B). These cytological findings suggested a parasitic cystic infestation and excision was advised. The histopathological findings confirmed the diagnosis of cysticercosis.

In this study, all cases of parasitic lesions showed mixed inflammatory response ranging from few histiocytes to diffuse mixed inflammatory cells. Presence of eosinophils were seen in only 7. Out of the 15 cases while lymphocytes, histiocytes, neutrophil, foreign body giant cells, and epithelioid granuloma were seen in 3, 6, 3, 2 and 1 cases, respectively. Dirty granular background was seen in 7 cases (Table 2).

cytomorphological findings of cysticercosis in those cases where the clinical or radiological diagnosis was differed.

Materials and Methods

The study of 15 cases conducted from tertiary care hospitals in Jaipur over a period of 24 months from June 2013 to June 2015. FNAC is an outpatient procedure. 15 patients, who had superficial palpable subcutaneous and intramuscular lump, underwent FNAC during this period. FNAC was performed with 22-gauge needle. Aspirated material was smeared on the glass slides. In cases of fluid aspirate from cystic lesion, smears were prepared from cystic fluid after cytocentrifugation, fixed in 95% ethanol and followed by staining done by papinacolau method. Subsequent excision biopsy was also evaluated. The histopathological findings were compared with the findings observed on cytological evaluation.

Table 1: Site of involvement and clinical diagnosis in 15 cases included in the present study

S. No.	Site	Clinical Diagnosis
1.	Right arm	Lipoma
2.	Right cheek	Sebaceous cyst
3.	Left neck	Reactive Lymphadenitis
4.	Right arm	Neurofibroma
5.	Abdominal wall	Benign tumor
6.	Left arm	Benign tumor
7.	Abdominal wall	Cysticercosis
8.	Right neck	Tuberculous lymphadenitis
9.	Left Breast	Fibroadenoma
10.	Left arm	Neurofibroma
11.	Abdominal wall	Benign tumor
12.	Right neck	Reactive lymphadenitis
13.	Left neck	Reactive Lymphadenitis
14.	Right axilla	Lipoma
15.	Right arm	Cysticercosis

Table 2: Clinical Diagnosis and No. of cases

S. No.	Clinical Diagnosis	No. of cases
1.	Lipoma	2
2.	Sebaceous Cyst	1
3.	Reactive Lymphadenitis	3
4.	Neurofibroma	2
5.	Cysticercosis	2
6.	Benign Tumor	3
7.	Tuberculous Lymphadenitis	1
8.	Fibroadenoma	1

Table 3: Cytological features in 15 cases included in present study

S. No.	Cytological Findings	No. of Cases
1.	Fragments of bladder wall of Cysticercus	4
2.	Eosinophils	7
3.	Hooklets	0
4.	Lymphocytes	3
5.	Histiocytes	6
6.	Neutrophils	3
7.	Foreign body Giant cells	2
8.	Epithelioid granuloma	1
9.	Dirty granular background	7

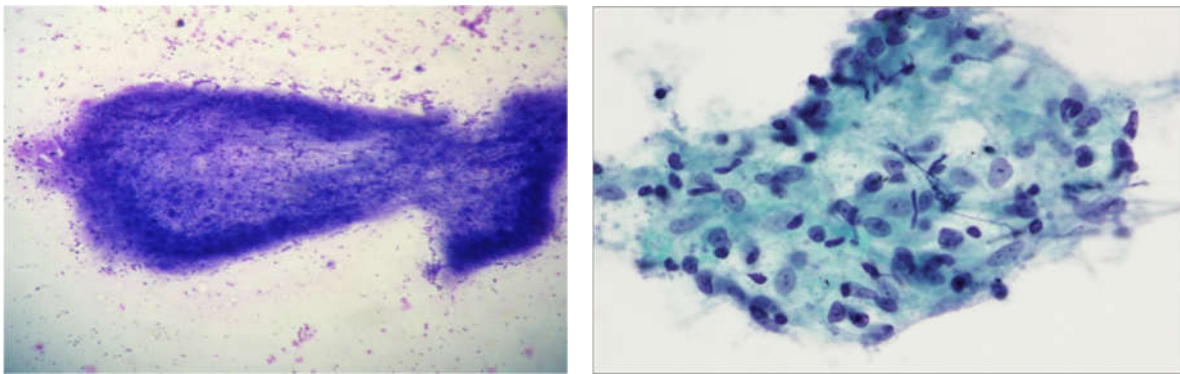


Figure 1: (A) Cytological smear showing bladder wall fragment of cysticercuscellulosae surrounded with inflammatory cells. (B) Aspirate showing a cluster of epithelioid histiocytes. (Papanicolaou stain).

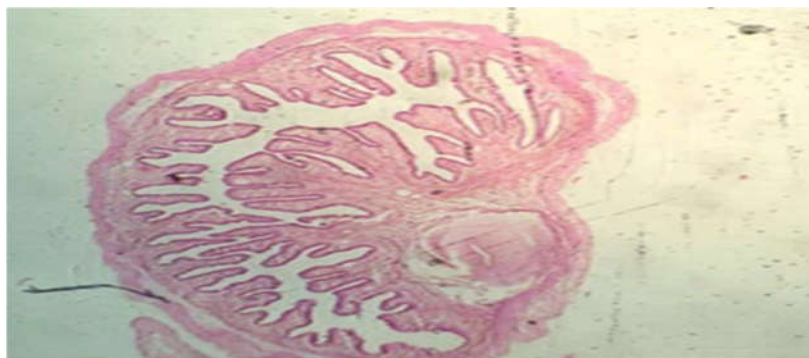


Figure 2: Photomicrograph of tissue sections showing cysticercus larva enclosed in a thin fibrous cyst wall (H and E)

Discussion

Cysticercosis in humans is an ancient disease and has even been detected in Egyptian mummies by

paleoparasitologists [16]. Cysticercosis is the larval stage infection of the cestode *Taenia solium*. The

definitive host are only humans and can also behave as intermediate hosts by ingestion of raw or poorly cooked vegetables or water contaminated with eggs or pork infested with larvae [17]. Cysticercosis is also common in vegetarians due to absence of proper sanitation standards in developing countries [18].

Fully developed cysticerci are opalescent, milky white cysts, congedated to oval m/s approximately 1 cm in full length. The cyst contains fluid and a single invaginated scolex. The scolex has a rostellum, 22–30 small hooklets and four suckers. The wall of the cyst is multilayered, 100–200 µm thick and covered by microvilli.

The cysticercosis infection presents most commonly as intramuscular or subcutaneous palpable nodule [19]. Most of these cases are clinically misdiagnosed as benign or malignant soft-tissue tumor or lymphadenitis depending on the site [20]. The diagnostic role of FNAC in cysticercosis was first emphasized by Kung et al. in 1989 [21]. Since then FNAC plays an important role in assessing subcutaneous or muscle nodules caused by parasites [20]. The cytomorphological identification of larvae in cytological smears by different observers has widened the diagnostic utility of FNAC in skin nodules [22, 23 and 24].

Essential for the cytodagnosis of cysticercosis is look for the fragments of parasite including its hooklets and bladder wall. The cytomorphology of cysticercosis varies from viable cysts through calcified to necrotic lesions. The most common finding in viable cysts is delicate fragments of bladder wall with tiny, parasitic nuclei in a clear, acellular background. The aspiration findings reveal fragments of bladder wall Aspirates of necrotic lesions may contain fragments of bladder wall, invaginated portions, including calcereous corpuscles and detached single hooklets. Parasitic fragments may comprise bluish, fibrillary structures, sometimes with clustering, thrown tegument into rounded wavy folds, calcospherules, scolex with hooklets, and hyaline membrane surrounding it [25–27].

The physical factors such as the firm non expansile nature of the host tissue may limit the parasite growth and start inflammatory response of the host. The presence of eosinophils, neutrophils, palisading histiocytes, giant cells, and atypical granular dirty background in an aspirate from a subcutaneous nodule should suggest a differential of parasitic infestation. Nonetheless, still in some cases of cysticercosis, none

of these features may be found, and the inflammation may differ [20]. Viable cysticerci may not cause any inflammation but when their degeneration occurs, there is inflammatory cells response, associated with foreign body giant cell reaction and variable granuloma. The viable cyst or calcified and necrotic lesions all have distinctive cytological features. The viable cyst aspirate is clear fluid and reveal bladder wall fragments in a clear acellular background. Finding an entire scolex in FNA is a rare event [28]. None of our cases showed hooklets or scolex on cytology.

The most common cause of intramuscular or subcutaneous palpable parasitic nodule is most commonly due to cysticerci. The similar clinical presentation by other parasites includes larval form of tapeworm and Multiceps and Spargana, larva of *Spirometra Mansonoides* [29]. Hydatid cyst caused by the larva of *Echinococcus Granulosus* can also occur in the subcutaneous tissue as an unusual presentation [30]. Cytomorphological details of the aspirate help to differentiate each other. The suckers and hooklets are present in Cysticerci and coenuri while absent in spargna. Multiple protoscolices are seen in Coenures while cysticerci has only one scolex, which is rarely seen in cytological findings [29]. Bladder wall is thin and membranous in cysticerci while it is lamellated and thicker in a hydatid cyst. The single scolex of cysticerci in aspirate is differentiated by multiple scolices of hydatid cyst.[29].

Conclusion

FNAC has emerged as an easy, quick, reliable, and sensitive diagnostic tool in identifying parasitic cyst. In FNAC smears if we are able to demonstrate parasitic bladder wall, tegument fragments, hooklets and calcareous corpuscles, it helps to give definitive diagnosis and avoid open excision biopsy in many cases.

Conflicts Of Interest: The authors declare that there is no conflict of interests regarding the publication of this paper.

Funding: Nil, **Conflict of interest:** None.

Permission of IRB: Yes

References

1. Mittal A, Gupta S, Gupta S, Mehta V. Subcutaneous and intramuscular cysticercosis: high-resolution

- sonography. *Indian J Dermatol Venereol Leprol*. 2009 Sep-Oct;75(5):515-6. doi: 10.4103/0378-6323.55404.
2. Craig P, Ito A. Intestinal cestodes. *Curr Opin Infect Dis*. 2007 Oct;20(5):524-32.
 3. García HH, Gonzalez AE, Evans CA, Gilman RH; Cysticercosis Working Group in Peru. *Taenia solium* cysticercosis. *Lancet*. 2003 Aug 16;362(9383):547-56.
 4. King CH. Cestodes (tapeworms). In: Mandell GL. (ed.) *Principles and practice of infectious diseases*. 6th ed. Philadelphia: Elsevier Churchill Livingstone; 2005, p. 3289.
 5. Garcia HH, Del Brutto OH. *Taenia solium* cysticercosis. *Infect Dis Clin North Am*. 2000 Mar;14(1):97-119, ix.
 6. Kraft R. Cysticercosis: an emerging parasitic disease. *Am Fam Physician*. 2007 Jul 1;76(1):91-6.
 7. Smiti S, Sripathi H, Naik L. Unusual location of cysticercus lesions in soft tissue-report of three cases. *Indian J Radiol Imaging* 2003; 13: 157-158.
 8. Mamere AE, Muglia VF, Simão GN, Belucci AD, Carlos dos Santos A, Trad CS, Takayanagui OM. Disseminated cysticercosis with pulmonary involvement. *J Thorac Imaging*. 2004 Apr;19(2):109-11.
 9. Pawlowski Z, Allan J, Sarti E. Control of *Taenia solium* taeniasis/cysticercosis: from research towards implementation. *Int J Parasitol*. 2005 Oct;35(11-12):1221-32.
 10. Allan JC, Velasquez-Tohom M, Garcia-Noval J, Torres-Alvarez R, Yurrita P, et al. Epidemiology of intestinal taeniasis in four, rural, Guatemalan communities. *Ann Trop Med Parasitol* 1996 Apr;90(2): 157-165.
 11. Allan JC, Velasquez-Tohom M, Torres-Alvarez R, Yurrita P, Garcia-Noval J. Field trial of the coproantigen-based diagnosis of *Taenia solium* taeniasis by enzyme-linked immunosorbent assay. *Am J Trop Med Hyg*. 1996 Apr;54(4):352-6.
 12. García HH, Gilman RH, Gonzalez AE, Verastegui M, Rodriguez S, Gavidia C, Tsang VC, Falcon N, Lescano AG, Moulton LH, Bernal T, Tovar M; Cysticercosis Working Group in Perú. Hyperendemic human and porcine *Taenia solium* infection in Perú. *Am J Trop Med Hyg*. 2003 Mar;68(3):268-75.
 13. Bourke GJ, Petana WB. Human *Taenia* cysticercosis: a bizarre mode of transmission. *Trans R Soc Trop Med Hyg*. 1994 Nov-Dec;88(6):680.
 14. Schantz PM, Moore AC, Muñoz JL, Hartman BJ, Schaefer JA, Aron AM, Persaud D, Sarti E, Wilson M, Flisser A. Neurocysticercosis in an Orthodox Jewish community in New York City. *N Engl J Med*. 1992 Sep 3;327(10):692-5.
 15. Willingham AL 3rd, Engels D. Control of *Taenia solium* cysticercosis/taeniosis. *Adv Parasitol*. 2006;61:509-66.
 16. R. Kraft, "Cysticercosis: an emerging parasitic disease," *American Family Physician*, vol. 76, no. 1, pp. 91-98, 2007.
 17. F. Bruschi, M. Masetti, M. T. Locci, R. Ciranni, and G. Fornaciari, "Short report: cysticercosis in an Egyptian mummy of the late ptolemaic period," *American Journal of Tropical Medicine and Hygiene*. 2006, 74, 598-99
 18. Kraft R. Cysticercosis: an emerging parasitic disease. *Am Fam Physician*. 2007 Jul 1;76(1):91-6.
 19. Suchitha S, Vani K, Sunila R, Manjunath GV. Fine needle aspiration cytology of cysticercosis-a case report. *Case Rep Infect Dis*. 2012;2012:854704. doi: 10.1155/2012/854704. Epub 2012 Jul 18.
 20. Sawhney M, Agarwal S. Cysticercosis: hooked by a hooklet on fine needle aspiration cytology-a case report. *Case Rep Infect Dis*. 2013;2013:315834. doi: 10.1155/2013/315834. Epub 2013 Aug 19.
 21. Kung IT, Lee D, Yu HC. Soft tissue cysticercosis. Diagnosis by fine-needle aspiration. *Am J Clin Pathol*. 1989 Dec;92(6):834-5.
 22. Vuong PN. Fine needle aspiration cytology of subcutaneous cysticercosis of the breast. Case report and pathogenic discussion. *Acta Cytol*. 1989 Sep-Oct;33(5):659-62.

23. Kung IT, Lee D, Yu HC. Soft tissue cysticercosis. Diagnosis by fine-needle aspiration. *Am J Clin Pathol.* 1989 Dec;92(6):834-5.

24. Verma K, Kapila K. Fine needle aspiration diagnosis of cysticercosis in soft tissue swellings. *Acta Cytol.* 1989 Sep-Oct;33(5):663-6.

25. Nigam S, Singh T, Mishra A, Chaturvedi KU. Oral cysticercosis--report of six cases. *Head Neck.* 2001 Jun;23(6):497-9.

26. Kamal MM, Grover SV. Cytomorphology of subcutaneous cysticercosis. A report of 10 cases. *Acta Cytol.* 1995 Jul-Aug;39(4):809-12.

27. V. K. Arora, K. Gupta, N. Singh, and A. Bhatia, "Cytomorphologic panorama of cysticercosis on fine

needle aspiration: a review of 298 cases," *ActaCytologica* 1994 May-Jun;38(3):377-80.

28. N. Singh, V. K. Arora, and A. Bhatia, "Are all subcutaneous parasitic cysts cysticercosis?" *ActaCytol* 2006 Jan-Feb;50(1):114-5.

29. Handa U, Garg S, Mohan H. Fine needle aspiration in the diagnosis of subcutaneous cysticercosis. *Diagn Cytopathol.* 2008 Mar;36(3):183-7. doi: 10.1002/dc.20792.

30. Singh N, Arora VK, Bhatia A. Are all subcutaneous parasitic cysts cysticercosis? *Acta Cytol.* 2006 Jan-Feb;50(1):114-5.

.....
How to cite this article?

Parakh R, Gupta S, Singh S, Garewal J, Rajput R, Vashit S. Role of FNAC in the diagnosis of cysticercosis. *Int J Med Res Rev* 2016;4(3):407-413. doi: 10.17511/ijmrr.2016.i03.22
.....