

A quadrupled semitendinosus only anterior cruciate ligament reconstruction with tibial suspensory fixation

Ballal MM¹, Chebbi P²

¹Dr. Madan Mohan Ballal, Assistant Professor, Sanjay Gandhi Institute of Trauma and Orthopaedics, Bangalore, Karnataka, India, ²Dr. Pavankumar Chebbi, Assistant Professor, Sanjay Gandhi Institute of Trauma and Orthopaedics, Bangalore, Karnataka, India.

Address of Correspondence: Dr. Pavankumar Chebbi, Email:pavanchebbi267@yahoo.co.in

.....

Abstract

Purpose: Study is designed to analyze the postoperative outcome of arthroscopic ACL reconstruction with quadrupled semitendinosus tendon autograft fixed in femoral tunnel using tight rope and in the tibial tunnel using suture disc. **Methods:** A prospective study on a continuous series of 102 patients, operated for ACL rupture, using the same technique, from September 2010 to March 2013. **Results:**The longest follow-up was at 24 months. At 2 year follow-up the mean International Knee Documentation Committee (IKDC 1999) evaluation score revealed that 63.7% had a normal overall grade A. The mean Lysholm score improved from 59.4 to 92.4 at follow-up. The improvement in the limb symmetry index by single hop test was statistically significant. Laxity assessment at 12 months showed 87.2% had a grade 0 or 1 Lachman laxity with a hard end point. Patients had no motion deficit and the knee was stable in deep flexion and retained their strength during internal rotation of the knee. **Conclusion:** a quadrupled semitendinosus graft was adequate in order to be used alone as a four-strand graft and to get a minimum length and thickness for our graft construct. This enhanced our post-operative rehabilitation by contribution to stability in deep flexion and retaining the strength during internal rotation of the knee. It is cost effective to use atightrope at the femoral end and suture disc at the tibial end as compared to an aperture fixation by a bioscrew.

Keywords: ACL reconstruction, suspensory fixation, suture disc, quadrupled semitendinosus graft, gracilis tendon sparing.

.....

Introduction

Anterior cruciate ligament rupture is the most common knee ligament injury. It is estimated that more than 200,000 ACL reconstructions are performed annually in the United States and the incidence of ACL injury is roughly one in 3,000 per year [1]. There have been significant technical advances during recent decades to treat ACL insufficiency and many studies have documented the successful results of contemporary arthroscopic ACL reconstruction [2]. The bone-patellar tendon-bone (BPTB) graft is considered as a gold standard as it has the least measurable laxity and the fastest graft incorporation with lowest failure rate [3]. However, there are several postoperative disadvantages of the BPTB graft, which include anterior knee pain, quadriceps weakness and extension deficit. The use of

the semitendinosus and gracilis (STG) tendons is becoming the choice method in anterior cruciate ligament (ACL) reconstruction. This graft, with four strands of STG tightened identically, presents the advantage of having a mechanical resistance theoretically superior to the mechanical resistance of a tendon from the patellar ligament with a minimum width of 10mm [4, 5]. During the last decade, there has been an increased use of hamstring tendon (HT) autografts [6]. Suspensory methods (that is, fixation outside the tunnel) and aperture methods (by interference screw close to the origin and insertion) of the autograft fixation have been described, with aperture fixation resulting in increased stiffness of the construction compared with the suspensory method. The femoral fixation of the STG tendons using an endobutton appeared to be reliable as well as sufficiently resistant and rigid [7]. However according to Adam *et al* [8] after suture disc fixation of a

Manuscript received: 15th Dec 2015
Reviewed: 31st Dec 2015
Author Corrected: 10th Jan 2016
Accepted for Publication: 19th Jan 2016

quadrupled tendon graft the construct had a lower linear stiffness and the graft slipped out of the bone tunnel at lower loads. Interference screw fixation of tendon grafts is preferable to suture disc fixation.

Our study is designed to analyze the postoperative outcome of arthroscopic ACL reconstruction with quadrupled semitendinosus tendon autograft fixed in femoral tunnel using TightRope and in the tibial tunnel using suture disc.

Material and Methods

This was a prospective study on a continuous series of 110 patients operated for ACL rupture, using the same technique, from September 2010 to March 2013.

All of the above mentioned authors were the operating surgeons. Arthrex - ACL TightRope® and suture disc were used.

The exclusion criteria were a previously operated knee, associated meniscal tears, ligament reconstruction of the contralateral knee, as well as observed chondral lesions that could modify the postoperative

rehabilitation protocol (grade III or IV cartilaginous lesions).

In all acute cases of ACL injury, patients were treated with long knee brace for three weeks following which ACL reconstruction was planned after bone oedema subsided. Out of 110 patients 4 patients didn't respond to follow up and 4 patients didn't follow rehabilitation protocol so were excluded from study. During that three weeks' period patient received preoperative physiotherapy exercises. The minimum follow-up of the clinical assessment was two years with mean follow up of 36 months. This series included 102 patients, with a mean age of 26 years (range all cases: 12—56 years), with 78 men and 12 women. Nature of injury in 48 patients was due to sports related injuries. Road traffic accidents being the cause for ACL tears in 37 patients and rest 15 patients' sustained injury due to other causes like slip and fall Majority of our patients, 56 of them fell into competitive lifestyle like joggers, athletes followed by sedentary lifestyle (33 patients) rest of them were into farming (11 patients). Our pre and post-operative protocol was similar to that of aperture fixation.

Pre-operative assessment: The pre-operative assessment included detailed history and physical examination, radiographs of the involved knee. Lachman test, anterior drawer test and Mc Intosh Pivot shift test were used for testing ACL. The Pivot shift test was performed under anesthesia. The results were graded as 0 (negative), 1+, 2+ and 3 + positive. Other tests performed routinely included the Varus and Valgus stress tests, Mc Murray's test, Posterior drawer test and the Reverse Pivot shift test. Radiographs included the standing AP view of both the knees with a lateral and notch views of the affected knees. MRI of the involved knee was taken in all the cases.

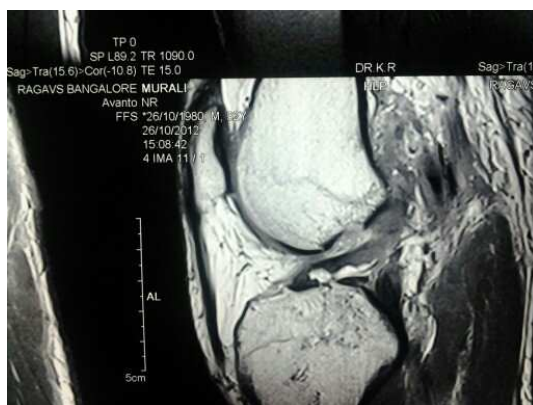

Fig.1: MRI showing ACL tear.

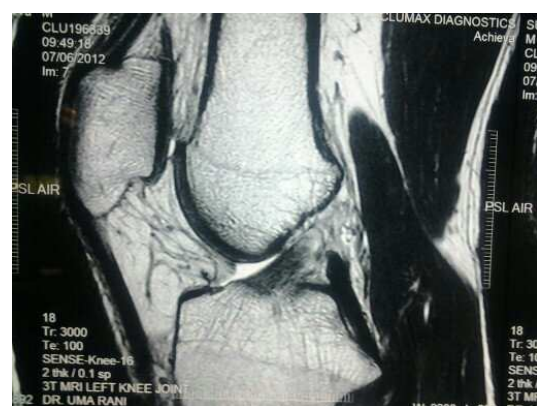

Fig.2: MRI showing ACL tear

Arthroscopic technique: After induction of anesthesia, supine position with upper thigh tourniquet. Clinical tests performed under anesthesia.

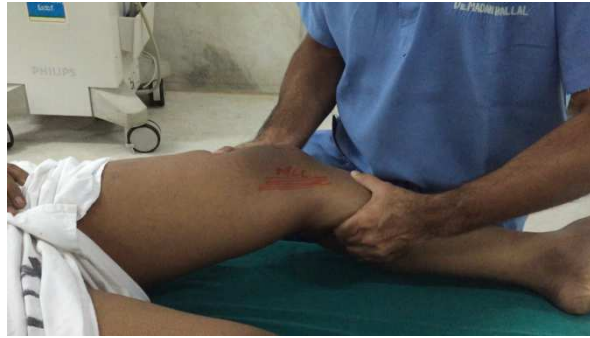

Fig 3: Lachman test

Initial diagnostic arthroscopy performed via anterolateral and anteromedial ports. Vertical incision about 3cm anteromedially on proximal tibia starting 3-4cm distal to joint line and 3-4cm medially to tibial tuberosity. A Semitendinosus graft used, the gracilis tendon was spared in all the cases. Semitendinosus tendon is more horizontal and lies below gracilis. It is pulled with curved clamp and snared with a braided suture, dissection carried proximally up the thigh. The insertion end of the tendon is held with ethibond suture and the surrounding fibrous extension released and the procured. ACL graft master used for pretensioning and control of tendon (fig.4). The overall length of the tendon is measured.

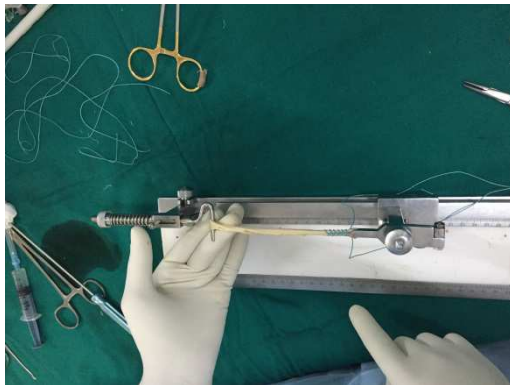

Fig.4: ACL graft master




Fig.5: Tightrope

The tendon is looped in half to make double strand of equal length. Place a double Krackow-type whipstitch in free end of each tendon with No. 5 Ethibond suture. Tightrope was used in all cases (fig.5) with the double stranded graft looped further to create a total of four strands and graft size measured with the tendon sizer. A quadrupled semitendinosus graft was used in all the cases with a minimum length of 6.5cms and a maximum of 7.5cms. The minimum thickness our graft

construct was 8mm in male and 7mm in female patients. Femoral tunnel preparation is done through low placed anteromedial port with knee in maximum flexion (>120degree). Entry point was attained by a 45 degree micro fracture pilot awl. The graduated guide pin was advanced so that it exits the femoral cortex the femoral tunnel length to be reamed was measured and then calculated according to the length of the graft material. We found the average femoral length to be 3.5cms.



Fig.6: Suture retriever through tibial tunnel pulling the Ethibond out

Using the appropriate diameter reamer, the femoral tunnel is reamed based on graft size. A no.5 Ethibond suture was attached to graduated guide pin is passed through anteromedial portal to the femoral tunnel exiting lateral aspect of thigh. Tibial guide placed taking the ACL footprint, which is anterior and medial to the anterior horn of the lateral meniscus in the

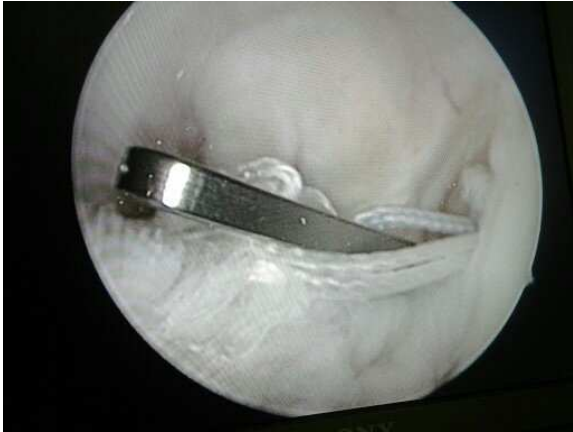

Fig.7: Endobutton entering femoral tunnel

The length of the tunnel is marked on the prepared graft by a 3-0 vicryl suture. Under arthroscopic visualization in the joint, once the marked line reaches the inner edge of the femoral tunnel (fig.7, fig.8), then counter traction

midline, the medial tibial spine, the PCL as reference points. Guide pin passed and cannulated reamer over it, as determined by the prepared graft diameter size. Using suture retriever (fig.6) through tibial tunnel the other end of Ethibond was pulled out and secured to the pre-tensioned graft with the endobutton attached tightrope and this is pulled out of the femoral tunnel, so that the thread is out of the thigh.

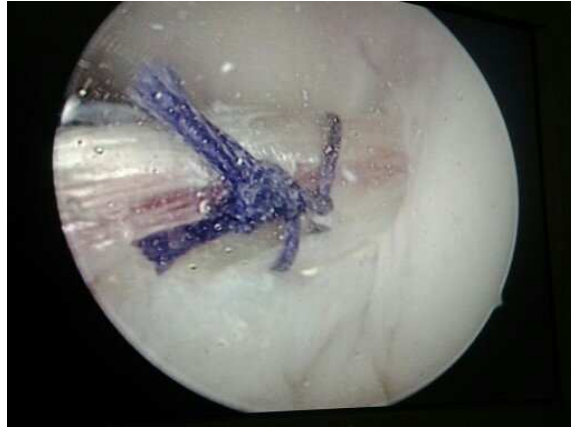


Fig.8: Marked line reaches inner edge of the femoral tunnel

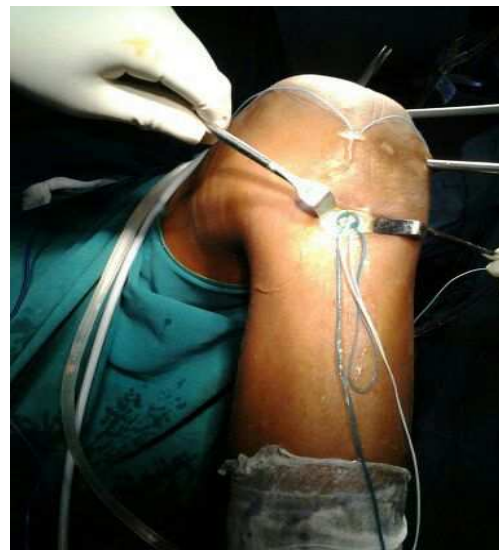femoral tunnel. The length of the graft in the femoral tunnel was reached at 2 cms, intra-articular length was 2cms and in the tibial tunnel 2cms of the graft was maintained. When tension is placed on the grafts, the knee is taken through approximately 15 to 20 cycles of



is given where the endobutton flips at the outer femoral cortex and it is confirmed by giving traction. Then the white shortening loop is pulled in a synchronized manner so that the graft is gradually pulled into the

Fig.9: Suture disc.

The tibial side of the graft was fixed in 20 degree of knee flexion with a suture disc which was held over the tibial tunnel by passing the ethibond suture threads through the suture disc and tightening the knots around the disc (fig.9, fig.10). If some amount of laxity were to be present after fixation, it was additionally tightened by further traction on the white



complete flexion and extension. This helps to align the grafts, will tension the sutures, and removes the slack of the graft, tests for impingement between the grafts and bony structures.

Fig.10: Tightening the knots around the disc

shortening loop in a synchronized manner so that the graft is gradually pulled into the femoral tunnel. The joint is cleared off the debris by thorough an arthroscopic lavage. Graft harvest site is sutured in layers with no. 2-0 vicryl. Skin closed with ethilon sutures or skin staples. Compression bandage dressing done and long knee extension brace applied.

Rehabilitation: Long knee brace was given for three weeks after surgery with gradual to partial weight bearing with the brace. Range of motion of the knee and isometric muscle exercises were started the day after the operation and gradually progressed on the basis of closed kinetic chain exercises. Knee flexion of more than 90° and walking with full weight bearing was allowed 15 days postoperatively.

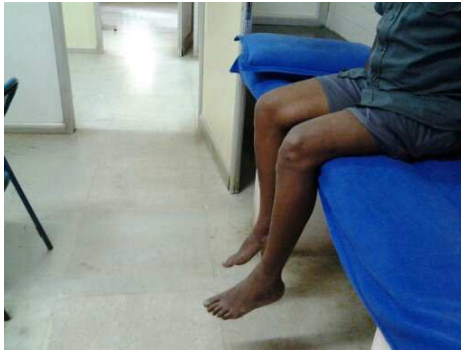

Fig.11: Knee flexion

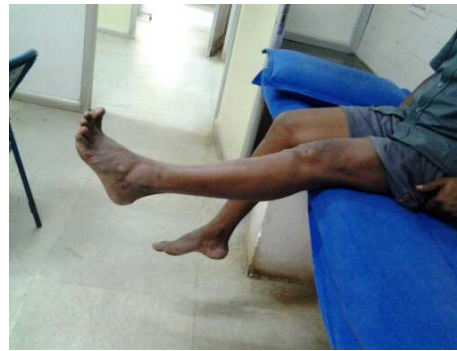

Fig.12: Knee extension

Indoor cycling and swimming were permitted after six weeks and running after 12 weeks. High demand pivoting sports activities were allowed after approximately 12 months.

Results

All the patients were examined at 3, 6, 12, and 24 months after surgery as well as at the latest follow-up. The clinical assessment involved the number of operative revisions and complications at the longest follow-up, the objective criteria of the International Knee Documentation Committee (IKDC 1999) [9] and Lysholm and Gillquist knee scoring system [10], Limb Symmetry Index scored by single leg hop test done at 6 months (LSI score) [11], laxity assessment by Lachman test at 12 months. The median hospital stay in our series was 4 days with a range of 3-5 days. Spinal anaesthesia was used in all of our cases. The mean time taken for surgery was 94.5 minutes with values ranging from 70 to 130 minutes.

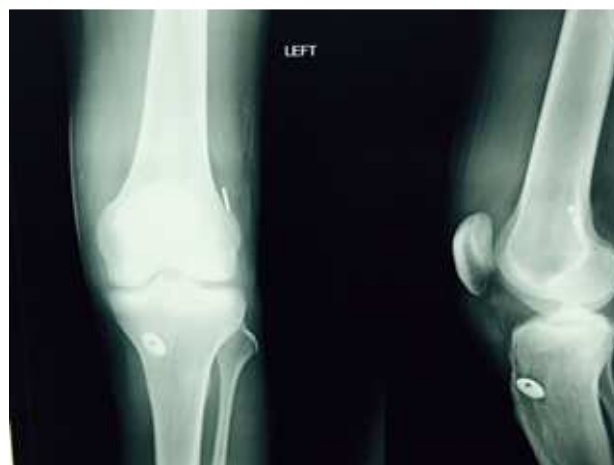

Fig.13: Postoperative radiograph

At two-year follow-up the mean IKDC evaluation score was revealed. The full IKDC assessment showed that 65 patients (63.7%) had a normal overall IKDC grade (A). The remaining patients 35 (34.3%) were graded as “nearly normal” (B). No joint was “abnormal” or “severely abnormal” (grade C or D).

The mean Lysholm score was 92.4 at follow-up improved from 59.4 preoperatively. 72 patients (70.6%) were rated as very good (91–100 points), 14(13.7%) as good (84–90 points) and 14(13.7%) as fair (65 to 83 points). None was assessed as poor (<65 points).

According to the subjective questionnaire (SQ) the satisfaction with the operative result was. 76 patients (74.5%) were very satisfied (SQ, 0-1) and 24(23.5%) were satisfied (SQ 2-3) with the result of the operation. None was dissatisfied (SQ, 4-5)

Single hop test done after surgery had the following results. LSI scores were calculated at 6 months after surgery. LSI scores improved postoperatively with mean of 80.69 SD 6.32 comparative to preoperative scores with mean of 50.19 SD 5.45 with a p value of < 0.001 which is statistically significant.

Postoperative laxity assessment was done at 12 months after surgery. 89(87.2%) patients had a grade 0 or 1 Lachman laxity with a hard end point. Three (2.9%) patients showed grade 3 Lachman laxity.

Range of motion was compared with the contralateral knee. At the final follow-up 75(73.52%) patients had no motion deficit and the knee was stable in deep flexion and retained their strength during internal rotation of the knee. 14(13.72%) patients had isolated flexion deficit of 10 degrees or less. 10(9.8%) patients had isolated extension deficit of 5 degrees or less. 3(2.98%) patients had both flexion and extension deficits at the final follow-up

Discussion

ACL reconstruction surgery is one of the most common procedures in sports traumatology [12]. The selection of the graft depends on the surgeon's preference and the available tissues. Among the autogenous tissues, the most commonly used grafts are currently the patellar tendon and the quadrupled hamstrings. Cooley *et al* in their study concluded that ACL reconstruction using quadrupled fold semitendinosus tendon autograft provides excellent clinical outcome, patients maintain pre injury activity without episodes of reinjures [13]. Leo *et al* reported that the technique of ACL reconstruction using quadrupled fold semitendinosus tendon autograft for ACL reconstruction using the Endobutton for femoral fixation has been used for over ten years with no known instance of fixation failure [14]. Fixation techniques outside the tibial tunnel (e.g., staples and interference screw fixation) require that the grafts exit the tibial tunnels for a certain distance [15]. In our study with suture disc only a quadrupled semitendinosus graft was used in all the cases with a minimum length of 6cms and a maximum of 7.5cms and we found it adequate for our suspensory fixation, thus avoiding the necessity of an additional gracilis tendon graft. Stergios *et al* concluded that the length of semitendinosus tendon, is usually inadequate in order to be used alone as a four-strand graft [16]. Other studies also have reported the use of semitendinosus and gracilis grafts to have good results [17,18,19], but their fixation method varied unlike ours where we only used suspensory fixation by suture disc. A Gobbi

recommended using only one tendon whenever possible because the semitendinosus alone seem to have an advantage over the semitendinosus and gracilis construct with regard to internal rotation weakness following harvest of two tendons. Furthermore, preservation of gracilis tendon offers stability in deep flexion and internal rotation strength and protects from further ACL injuries [20]. According to Vernon *et al*, the use of semitendinosus tendon alone is adequate in almost all cases and the rate of insufficiency for a quadrupled reconstruction is only one in 300 cases and is almost always the result of improper graft harvest [21]. The minimum thickness our graft construct was 8mm and 7mm in male and female patients respectively. The average diameter of the normal ACL is 11 mm; therefore, a graft of minimum thickness of 7 mm is recommended [22,23,24]. The thicker the graft is the stronger and stiffer the graft will be. The biomechanical properties of the graft are certainly affected by its diameter. Soft tissue grafts may also have a tendency to cause tunnel widening [25,26]. However, this is unknown to be a function of the soft tissue graft if used with a suspensory fixation [27, 28]. In the present study we have not assessed the above as we never re-scoped and none of our cases required a revision reconstruction.

Konget *et al* concluded that Endobutton femoral fixation showed good results comparable to those of cross pin fixation in hamstring ACL reconstruction [7]. The increased elongation to cyclical loading in the suture

disc group indicates that there is more chance of residual laxity of graft fixed with suture disc [8]. However, biomechanical testing of fixation by interference screws has shown failures of fixation during cyclical loading of the hamstring construct [29, 30]. Adam F. *et al* noted that hamstring graft fixation with bioscrew and suture disc displayed less stiffness and early graft motion compared to patellar tendon grafts fixation. Moreover, for a hamstring graft, aperture fixation makes the graft construct more anatomic for tibial fixation and it offers greater stiffness and less graft motion inside the tibial tunnel hence interference screw fixation of tendon grafts is preferable to suture disc fixation [8]. In this study 73.52% had no range of motion deficits, 83.33% of patients had no flexion deficits. 87.2% of patients had a grade 0 or 1 Lachman laxity at 12 months post-surgery; however in our study laxity didn't affect the functional outcome. Our mean Lysholm score improved from 59.4 preoperative to 92.4 postoperatively. In S Plaweski *et al* 2009 series with a mean follow-up time of 51 months the Lysholm score improved from a mean preoperative value of 72.1 to mean value of 94.1 at the final follow-up [31]. Considerable improvement was found in LSI scores from mean of 50.19 (SD 5.45) to 80.69 (SD 6.32) which was found to be statistically significant. 74.5 % of the patient were satisfied with the operation as assessed by subjective questionnaire (SQ scoring). IKDC scoring was normal in 63.7 % cases and in rest 34.3% cases it was near normal.

Complications included superficial wound infection which developed in two (1.2%) out of 102 patients at the tibial fixation site. Both the cases were managed with antiseptic dressings and oral antibiotics for 1 week. 36 (35.2%) patients complained of numbness over the anterior aspect of leg. In a study by Spicer *et al* areas of sensory change over the front of the knee were identifiable in 50% of the patients and of these 86% demonstrated sensory changes in the distribution of the infragenicular branch of the saphenous nerve [32].

Conclusion

In our study we used a quadrupled semitendinosus graft; the gracilis tendon was spared in all the cases. We found it adequate in order to be used alone as a four-strand graft and to get a minimum length of 6cms, minimum thickness of 8mm in males and 7mm in females for our graft construct. This enhanced our post-operative rehabilitation by contribution to stability in deep flexion and retaining the strength during internal

rotation of the knee. We found it cost effective to use atightrope at the femoral end and suture disc at the tibial end as compared to an aperture fixation by a bioscrew. As discussed the incidence of laxity in our study is very minimal nevertheless laxity didn't affect the functional outcome. Our results were good with suspensory fixation at tibial end contrary to the previous studies.

Funding: Nil, **Conflict of interest:** None.

Permission of IRB: Yes

References

1. Tiago Lazzaretti Fernandes, Douglas Badillo Ribeiro, Diogo Cristo da Rocha, Cyro Albuquerque, César Augusto, André Pedrinelli *et al*. Description of an evaluation system for knee kinematics in ligament lesions, by means of optical tracking and 3D tomography. *Revista Brasileira de Ortopedia* 2014; 49(5):513-519.
2. Prodromos CC, Han YS, Keller BL, Bolyard RJ. Stability results of hamstring anterior cruciate ligament reconstruction at 2- to 8-year follow-up. *Arthroscopy*. 2005 Feb;21(2):138-46.
3. Hospodar SJ, Miller MD. Controversies in ACL reconstruction: bone-patellar tendon-bone anterior cruciate ligament reconstruction remains the gold standard. *Sports Med Arthrosc*. 2009 Dec;17(4):242-6. doi: 10.1097/JSA.0b013e3181c14841.
4. IS Corry, JM Webb, AJ Clingeffer, LA Pinczewski. Arthroscopic reconstruction of the anterior cruciate ligament A comparison of patellar tendon autograft and four-strand hamstring tendon autograft. *The American Journal of Sports Medicine* 1999; 27(4): 444-454.
5. Roe J, Pinczewski LA, Russell VJ, Salmon LJ, Kawamata T, Chew M. A 7-year follow-up of patellar tendon and hamstring tendon grafts for arthroscopic anterior cruciate ligament reconstruction: differences and similarities. *Am J Sports Med*. 2005 Sep;33(9):1337-45. Epub 2005 Jul 7.
6. Reinhardt, Keith R, Iftach Hetsroni, and Robert G. Marx. Graft selection for anterior cruciate ligament reconstruction: a level I systematic review comparing failure rates and functional outcomes. *Orthopedic Clinics of North America* 2010; 41(2): 249-262.

7. Chae-Gwan Kong, Yong In, Geon-Hyeong Kim, and Chi-Young Ahn, Cross pins versus endobutton femoral fixation in hamstring anterior cruciate ligament reconstruction: minimum 4-year follow-Up. *Knee surgery & related research*2012; 24(1):34-39.
8. Frank Adam, Dietrich Pape, Karin Schiel, Oliver Steimer, Dieter Kohn, and Stefan Rupp. Biomechanical properties of patellar and hamstring graft tibial fixation techniques in anterior cruciate ligament reconstruction Experimental study with roentgen stereometric analysis. *The American journal of sports medicine* 2004;32(1):71-78
9. James J. Irrgang, Allen F. Anderson, Arthur L, Boland, Christopher D. Harner, Masahiro Kurosaka, PhillipeNeyret, et al. Development and validation of International Knee Documentation Committee Subjective Knee Form. *The American Journal of Sports Medicine*, 2001;29(5):600-613.
10. Lysholm J, Gillquist J.Evaluation of knee ligament surgery results with special emphasis on use of a scoring scale. *Am J Sports Med.* 1982 May-Jun;10(3):150-4.
11. Frank R. Noyes, Sue D. Barber and Robert E. Mangine, Abnormal lower limb symmetry determined by function hop tests after anterior cruciate ligament rupture. *The American Journal of Sports Medicine*, 1991; 19(5):513-518.
12. Majewski M, Susanne H, Klaus S.Epidemiology of athletic knee injuries: A 10-year study. *Knee.* 2006 Jun;13(3):184-8. Epub 2006 Apr 17.
13. Cooley, Vernon J., Kathleen T. Deffner, and Thomas D. Rosenberg. Quadrupled semitendinosus anterior cruciate ligament reconstruction: 5-year results in patients without meniscus loss. *Arthroscopy: The Journal of Arthroscopic & Related Surgery*2001; 17(8):795-800.
14. Chen L, Cooley V, Rosenberg T. ACL reconstruction with hamstring tendon. *Orthop Clin North Am.* 2003 Jan;34(1):9-18.
15. Randy Schwartzberg, Bradd Burkhart, and Christopher Lariviere, Prediction of Hamstring Tendon Autograft Diameter and Length for Anterior Cruciate Ligament Reconstruction, *Am J Orthop.* 2008;37(3):157-159.
16. Papastergiou G, Stergios, Konstantinidis A, Georgios, Natsis Konstantinos, PapathanasiouEfthymia, Koukoulias Nikolaos, and Papadopoulos G. Alexandros. Adequacy of Semitendinosus Tendon Alone for Anterior Cruciate Ligament Reconstruction Graft and Prediction of Hamstring Graft Size by Evaluating Simple Anthropometric Parameters. *Anatomy Research International* Volume 2012, Article ID 424158, 8 pages doi:10.1155/2012/424158
17. Maurilio Marcacci, Stefano Zaffagnini, Francesco Iacono, Alberto Vascellari, Ivano Loreti, Elisaveta et al, Intra- and extra-articular anterior cruciate ligament reconstruction utilizing autogeneous semitendinosus and gracilis tendons: 5-Year clinical results, *Knee Surgery, Sports Traumatology, Arthroscopy* 2003;11(1):2-8.
18. Howell SM, Deutsch ML. Comparison of endoscopic and two-incision techniques for reconstructing a torn anterior cruciate ligament using hamstring tendons. *Arthroscopy.* 1999 Sep;15(6):594-606.
19. S. M. Howell. Gold standard-DLSTG graft, Presented at AAOSM Specialty Day New Orleans, Louisiana, USA, 2003.
20. A. Gobbi. Double bundle ACL reconstruction Using Only the Semitendinosus. *ISAKOS Current concepts*, winter 2007.
21. V. Cooley and K. Deffner. Quadrupled semi-T anterior cruciate ligament reconstruction: tips, techniques, and results. *Techniques in Orthopaedics*, 2005; 20(3):207-210.
22. J. A. Feller, R. Siebold, and K. E. Webster, ACL reconstruction in females: patellar tendon versus hamstring tendon autograft,” in *Journal of Bone and Joint Surgery B* 2005; 87(3):305.
23. Grood ES, Walz-Hasselfeld KA, Holden JP, Noyes FR, Levy MS, Butler DL, Jackson DW, Drez DJ. The correlation between anterior-posterior translation and cross-sectional area of anterior cruciate ligament reconstructions. *J Orthop Res.* 1992 Nov;10(6):878-85.
24. M. Hamada, K. Shino, S. Horibe, T. Mitsuoka, Y. Toritsuka, and N. Nakamura, “Changes in cross-sectional area of hamstring anterior cruciate ligament

grafts as a function of time following transplantation," *Arthroscopy*, 2005;21(8):917-922.

25. L'Insalata JC, Klatt B, Fu FH, Harner CD. Tunnel expansion following anterior cruciate ligament reconstruction: a comparison of hamstring and patellar tendon autografts. *Knee Surg Sports Traumatol Arthrosc* 1997; 5:234-238.

26. Webster KE, Feller JA, Hameister KA. Bone tunnel enlargement following anterior cruciate ligament reconstruction: a randomised comparison of hamstring and patellar tendon grafts with 2- year follow-up. *Knee Surg Sports Traumatol Arthrosc* 2001; 9:86-91.

27. Baumfeld JA, Diduch DR, Rubino LJ, Hart JA, Miller MD, Barr MS, Hart JM. Tunnel widening following anterior cruciate ligament reconstruction using hamstring autograft: a comparison between double cross-pin and suspensory graft fixation. *Knee Surg Sports Traumatol Arthrosc* 2008; 16:1108-1113.

28. Hersekli MA, Akpınar S, Ozalay M. Tunnel enlargement after arthroscopic anterior cruciate ligament reconstruction: comparison of bone-patellar

tendon-bone and hamstring autografts. *Adv Ther* 2004; 21:123-131.

29. Harvey AR, Thomas NP, Amis AA. The effect of screw length and position on fixation of four-stranded hamstring grafts for anterior cruciate ligament reconstruction. *Knee*. 2003 Mar;10(1):97-102.

30. Giurea M, Zorilla P, Amis AA, Aichroth P. Comparative pull-out and cyclic-loading strength tests of anchorage of hamstring tendon grafts in anterior cruciate ligament reconstruction. *Am J Sports Med*. 1999 Sep-Oct;27(5):621-5.

31. Plaweski, S., J. Rossi, and P. Merloz. Anterior cruciate ligament reconstruction: Assessment of the hamstring autograft femoral fixation using the EndoButton CL®. *Orthopaedics & Traumatology: Surgery & Research*, 2009;95(8):606-613.

32. Spicer DD, Blagg SE, Unwin AJ, Allum RL. Anterior knee symptoms after four-strand hamstring tendon anterior cruciate ligament reconstruction. *Knee Surg Sports Traumatol Arthrosc*. 2000;8(5):286-9.

.....
How to cite this article?

Ballal MM, Chebbi P. A quadrupled semitendinosus only anterior cruciate ligament reconstruction with tibial suspensory fixation. *Int J Med Res Rev* 2016;4(1):38-46. doi: 10.17511/ijmrr.2016.i01.006.
.....