

Titanium Reconstruction Nailing For Sub - Trochanteric Fractures of Femur

Jose Ashish K¹, Surendher Kumar R², Krishnagopal R³, Sandeep MMR⁴

¹Dr Ashish Kumar Jose, ²Dr Surendher Kumar R, ³Dr Krishnagopal R, ⁴Dr Sandeep MMR. All are affiliated with Department of Orthopedics, Mahatma Gandhi Medical College & Research Institute, Pondicherry, India

Address for correspondence: Dr Ashish Kumar Jose, Email: joseashish@yahoo.co.in

Abstract

Introduction: Sub-trochanteric fractures of femur present a challenging situation to the orthopaedic surgeons worldwide. Complications like malunion, nonunion and implant failure are high. Several implants have been designed for fixation of sub-trochanteric fractures. In this study we analyze the functional and radiological outcome of sub-trochanteric fractures treated by Titanium Reconstruction nails. **Methods:** This is a prospective study. 20 patients with sub-trochanteric fractures treated by Titanium reconstruction nail from June 2012 to December 2014 were included in the study. We analyzed these 20 patients for functional and radiological outcome and complications. **Results:** The fracture union rate was 100 % and the average union time was 14 weeks. 3 patients had varus malunion and shortening was noted in 4 patients. 85% of the patients had excellent to good functional outcome. **Conclusion:** We concluded that Titanium Reconstruction nail is an ideal implant for sub-trochanteric fractures with an excellent union rate and a very good functional outcome.

Keywords: Sub-trochanteric fracture, Titanium Reconstruction nail.

Introduction

Sub-trochanteric femoral fractures present a challenging situation to the Orthopaedic surgeons. It is one of the most difficult fractures to treat and the reported mortality ranges from 8.3% to 20.9% [1,2]. It has a bimodal age distribution with very different mechanisms of injury [3,4,5,6]. Younger age groups typically sustain these fractures as a result of high energy trauma and are often associated with other fractures, whereas in older age groups, these fractures are seen with low velocity trauma. These fractures are reported in children also [3,6,7]. Sub-trochanteric fractures are notorious for high complication rates and difficulty in treatment [8]. The reasons being:

- Most of the fractures are unstable.
- Powerful muscular attachment on both proximal and distal fragments pull them apart, making a stable fixation difficult.
- It is a junctional zone between cortical and cancellous bone and having less blood supply leading to delayed

healing.

Complications like malunion, nonunion and implant failure are high due to the above said reasons and also due to the biomechanically asymmetrical loading pattern in this region [1,2]. Restoration of femoral length and rotation and correction of femoral head and neck angulation to restore adequate abductor tension and strength are essential to restoring maximal ambulatory capacity. There are many implants for fixation of subtrochanteric fractures. In this study we analyze the functional and radiological outcome of sub-trochanteric fractures treated by Titanium Reconstruction nails.

We have planned this study to analyze the functional and radiological outcome of sub-trochanteric femoral fractures treated with Titanium Reconstruction nail.

Materials and Methods

This is a prospective study. We had 20 patients with sub-trochanteric fractures treated by Titanium reconstruction nail from June 2012 to December 2014.

Manuscript received: 10th Aug 2015
Reviewed: 19th Aug 2015
Author Corrected: 27th Aug 2015
Accepted for Publication: 14th Sept 2015

Of the 20 patients 16 were male and 4 were female with 12 patients injuring their right hip and 8 injuring their left hip. The mean age was 55 years (43- 74 years). We

analyzed these 20 patients for functional and radiological outcome and complications.

Inclusion criteria:

All traumatic sub-trochanteric fractures treated with Titanium Reconstruction nail were included in the study. (Figs.1, 2)

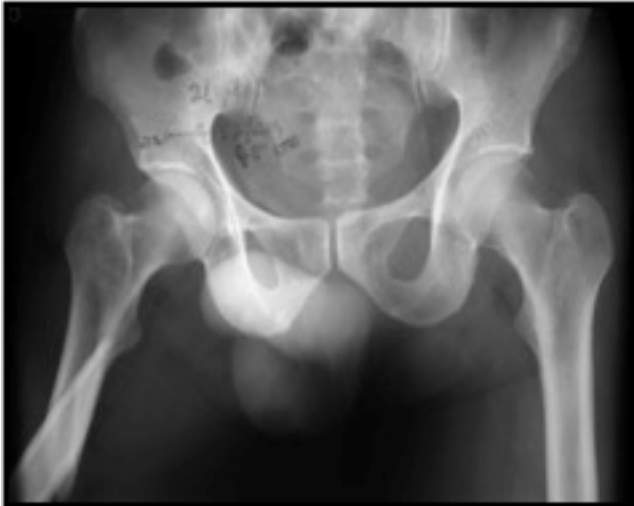

Fig.1: Pre-operative X-Ray

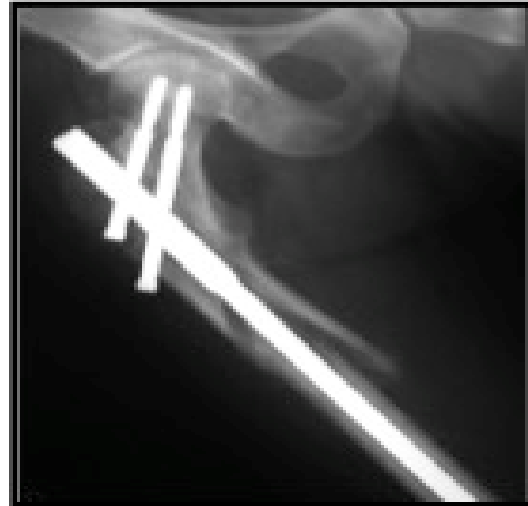


Fig 2: Immediate post-operative X-Ray

Exclusion criteria:

Sub-trochanteric fractures treated with stainless steel reconstruction nail, other implants, pathological fractures and open fractures were excluded from this study.

Mode of Injury:

1. Road Traffic Accident (18 patients)
2. Trivial fall (2 patients)

All the 20 patients were treated with Titanium reconstruction nail.

Post Operative Protocol

1. Sit propped up and do active quadriceps exercise on 1st post-operative day (POD).
2. Made to stand on the 2nd POD.
3. Partial weight bearing from 3rd POD (protected).
4. Sutures removed on 12th POD.
5. Full weight bearing once there is radiological signs of union .
 6. Assessment functionally & radiologically at 6 weeks, 12 weeks, monthly until fracture union and every 6 months thereafter. (Figs. 3,4,5)

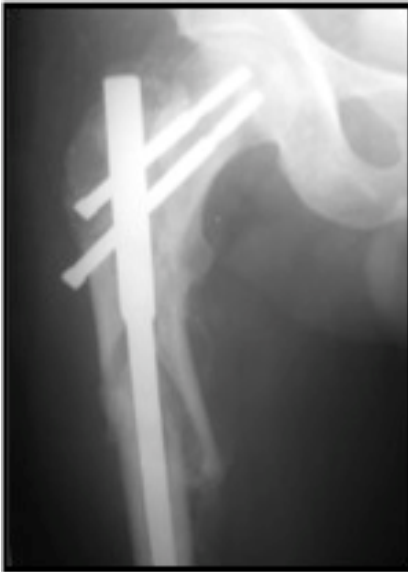

Fig 3: 6 weeks follow up X-Ray

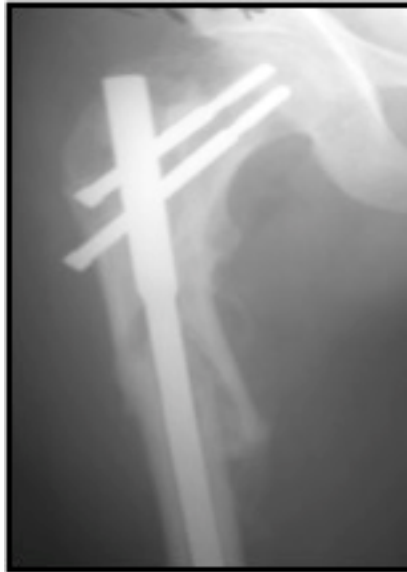

Fig 4: 12 weeks follow up X-Ray

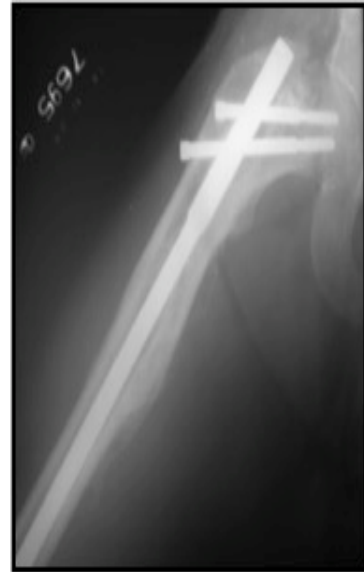

Fig 5: 6 months follow up X-Ray

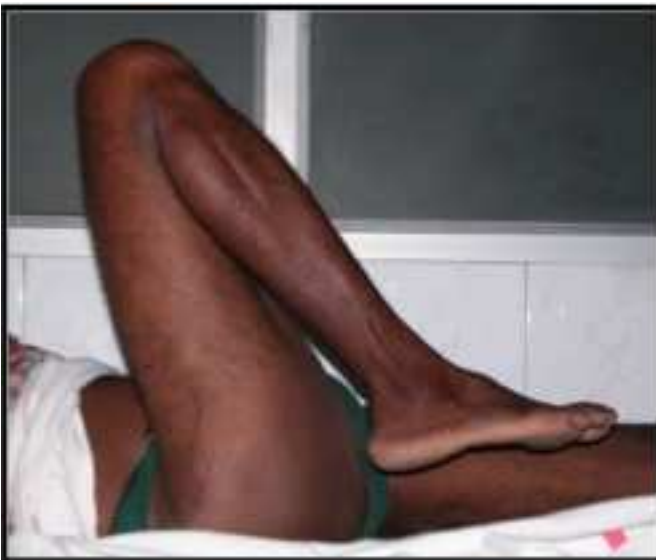

Fig.6: Full range of hip flexion

Scoring System

All patients were followed up until fracture union occurred. Kyle's criteria was used to evaluate the functional outcome [8] :

- I. Excellent :
 - No or minimum limp
 - Absence of pain
 - Full range of motion
- II. Good :
 - Mild limp
 - Mild occasional pain
 - Full range of motion
- III. Fair :
 - Moderate limp
 - Moderate pain
 - Limited range of movement

IV. Poor :

- Wheelchair bound
- Pain on any position
- Non-ambulatory

The fractures were classified according to Seinsheimer's Classification [2] :

- Type I - nil
- Type II A – 2 Patients
- Type II B – 4 Patients
- Type II C – 3 Patients
- Type III A – 2 Patients
- Type III B – 3 Patients
- Type IV - 4 Patients

- Type V - 2 Patients

Results

Duration of follow up: 6 months to 2 years

Mean follow up: 8 months

Based on the scoring system, the results of our study are

- Excellent : 4 patients
- Good : 13 patients
- Fair : 3 patients
- Poor : Nil

Union rate: 100 %

Union time: 12 weeks to 18 weeks (Average 14 weeks)

Varus malunion: 3 patients

Shortening: 4 patients

Infection: 1 patient

Non union: Nil

Delayed union: Nil

Implant Failure: Nil

Discussion

Sub-trochanteric fractures account for about 5-20% of all hip fractures. They are one of the most difficult fractures to treat because of the powerful muscles attached in this region [3,6], and the biomechanics of this segment of femur which is subjected not only to axial loads of weight bearing but also to tremendous bending forces because of eccentric load application on the femoral head [4]. Once the fracture is fixed these muscular forces act on the implant causing undue stress to the implant [9,10].

Moreover sub-trochanteric area has an asymmetrical loading pattern with medial cortex in compression (1200 lbs /inch²) and lateral cortex in tension (1000 lbs/ inch²) [11]. Frankel and Burstein, studying the effects of stress on proximal femoral fixation devices in patients during bed rest, demonstrated that significant forces are placed on the hip and proximal femur during hip flexion and extension and even while the patient is recumbent [12]. Further more, the cortical bone in the sub-trochanteric region is less vascular than the cancellous bone in the intertrochanteric region. Therefore, the risk of healing complication is higher [2,3].

A thorough understanding of the anatomy and biomechanics of asymmetrical loading pattern is necessary to choose the modality of treatment and the implant to overcome the complication and to avoid implant failure.

Fracture union Rate: In our study the union rate in was 100 %. French et al [13], Taylor et al [14] had reported 100 % union rate in their study and Hoover et al reported 90 % union rate [15].

Union Time: In our study, we had an average union time of 14 weeks. French et al reported 13.5 weeks as the average union time in his study [13]. Taylor et al reported average union time of 13 weeks in his study [14].

Varus Malunion: The angle formed by the axis of the femoral neck and femoral shaft ranges from 126⁰ to 130⁰. If the angle is decreased it is said to have varus malunion [6]. The primary reason for this was failure to counteract the muscle forces acting on the proximal fragment combined with adducted position of the distal femur during portal creation [13]. It is also important to get a good medial bone support by anatomical reduction with cortical bone continuity to avoid varus malunion [5].

In our study, 3 patients had varus malunion. It was attributed to the inadequate medial bone support due to comminution. In our study varus malunion was seen in 15% of the cases. French et al reported 21 % [13], Hoover et al reported 27 % in their series [15].

Iatrogenic fracture: In our study, there were no iatrogenic fractures. French et al reported 5 % of iatrogenic fracture in his series [13].

Implant failure: Our study did not account for any implant failure which is same as the literature available.

Shortening: In our study, 4 patients had shortening. The average shortening was 1.4 cm. In our study shortening accounted to 20%. French et al reported 5 % [13], and Hoover et al reported 23 % in their series [15].

Infection: In our study, 1 patient had superficial wound infection that settled with daily dressing and antibiotics. Infection rate in our study was 5%. Infection rate was nil in the study of French et al [13], Taylor et al [14], and Hoover et al [15].

Blood loss: Average blood loss in our study was 350 ml. French et al had 340ml [13], Taylor et al had 620 ml [14], Hoover et al had 480 ml in their study [15].

Scoring result: In our study, excellent and good result accounted to 85 % (17 patients). (Fig.6)

Conclusion

Titanium Reconstruction nail is an ideal implant for sub-trochanteric fractures. Irrespective of the implant used, it is important to get a good medial bone support by anatomical reduction, with cortical bone continuity, to prevent varus malunion. Implant failure rate is low in Reconstruction nail since nail is a load sharing device. Infection rate is relatively less and there is very good union rate.

Funding: Nil

Conflict of interest: None.

Permission of IRB: Yes

1. Pugh KJ, Morgan RA, Gorczyca JT, Pienkowski D. A mechanical comparison of subtrochanteric femur fracture fixation. *J Orthop Trauma*. 1998 Jun-Jul;12(5):324-9.
2. Seinsheimer F. Subtrochanteric fractures of the femur. *J Bone Joint Surg Am*. 1978 Apr;60(3):300-6.
3. Bedi A, Toan Le T. Subtrochanteric femur fractures. *Orthop Clin North Am*. 2004 Oct;35(4):473-83.
4. Kinast C, Bolhofner BR, Mast JW, Ganz R. Subtrochanteric fractures of the femur. Results of treatment with the 95 degrees condylar blade-plate. *Clin Orthop Relat Res*. 1989 Jan;(238):122-30.
5. Nungu KS, Olerud C, Rehnberg L. Treatment of subtrochanteric fractures with the AO dynamic condylar screw. *Injury*. 1993 Feb;24(2):90-2.
6. Sims SH. Subtrochanteric femur fractures. *Orthop Clin North Am*. 2002 Jan;33(1):113-26, viii. 208.
7. Lunsjo K, Ceder L, Tidermark J, Hamberg P, Larsson BE, Ragnarsson B, Knebel RW, Allvin I, Hjalmarsson K, Norberg S, Fornander P, Hauggaard A, Stigsson L. Extramedullary fixation of 107 subtrochanteric fractures: a randomized multicenter trial of the Medoff sliding plate versus 3 other screw-plate systems. *Acta Orthop Scand*. 1999;70:459-466.
8. Kyle RF, Gustilo RB, Premer RF. Analysis of six hundred and twenty-two intertrochanteric hip fractures. *J Bone Joint Surg Am*. 1979 Mar;61(2):216-21.
9. Cochran, G.V.B. Implantation of strain gages on bone in vivo. *J. Biomech*. 1972;5:119-123.
10. Fielding JW, Cochran GV, Zickel RE. Biomechanical characteristics and surgical management of subtrochanteric fractures. *Orthop Clin North Am*. 1974 Jul;5(3):629-50.
11. Koch, JC. The laws of bone architecture. *Am J Anat*. 1917;21(2):177-298.
12. Frankel, VH, Burstein, AH. *Orthopaedic Biomechanics*. Lea & Febiger, Philadelphia; 1970.
13. French BG, Tornetta P, 3rd. Use of an interlocked cephalomedullary nail for subtrochanteric fracture stabilization. *Clin Orthop Relat Res* 1998-348:95-100.
14. Taylor DC, Erpelding JM, Whitman CS, Kragh JF Jr. Treatment of comminuted subtrochanteric femoral fractures in a young population with a reconstruction nail. *Mil Med*. 1996 Dec;161(12):735-8.
15. Hoover GK, Browner BD, Cole JD, Comstock CP, Cotler HB. Initial experience with a second generation locking femoral nail: the Russell-Taylor reconstruction nail. *Contemp Orthop*. 1991 Sep;23(3):199-

How to cite this article?

Jose Ashish K, Surendher Kumar R, Krishnagopal R, Sandeep MMR. Titanium Reconstruction Nailing For Sub - Trochanteric Fractures of Femur. *Int J Med Res Rev* 2015;3(8):847-851. doi: 10.17511/ijmrr.2015.i8.159.