

Outcome analysis of post reduction pauwels angle in fracture neck of femur treated with dynamic hip screw or 6.5 mm cancellouscannulated screw fixation

Ganvir A¹, Sirsikar A², Gupta S³

Dr. Ajit Ganvir, Assistant Professor, Department Of Orthopaedics, Gandhi Medical College, Bhopal (Madhya Pradesh), Dr. Ashish Sirsikar, Assistant Professor, Department Of Orthopaedics, Gajra Raja Medical College, Gwalior (Madhya Pradesh), Dr. Sameer Gupta, Professor and Head, Department of Orthopaedics, Gajra Raja Medical College, Gwalior, Madhya Pradesh, India

Address for correspondence: Dr Ajit Ganvir, Email: ajitmedico@yahoo.com

Abstract

Introduction: Fracture within the neck region of intracapsular area of hip known as fracture neck of femur. Radiologically breakage in shenton's line is diagnosed as a fracture of neck of femur. Still this fracture remains an enigma to the Orthopaedic surgeon and is called as unsolved fracture. **Aim of study:** This study is undertaken to assess the correlation between post reduction Pauwel's angle and union rate in the fracture neck of femur treated with either Dynamic Hip Screw or CannulatedCancellous Screw fixation. **Materials and Methods:** This was a prospective study from June 2006 to October 2008. The study included 48 patients who underwent Dynamic Hip Screw and CannulatedCancellous Screw fixation for fracture neck of femur. **Results:** This study evaluated Post reduction Pauwel's angle for both types of fixation. Data analysis showed that with rise in Post reduction Pauwel's angle, union rate decreases in both types of fixation. **Conclusion:** Post reduction Pauwel's angle is a good guide to know the stability of fractures and decrease in this angle corrects shearing instability of the fracture site. This study gives an indication that with a vertical fracture line, a valgus osteotomy might help in decreasing the incidence of non union.

Keywords: Fracture neck of femur, Post reduction Pauwels angle, Dynamic hip screw, Cannulatedcancellous screw and Union.

Introduction

Fracture within the neck region i.e. capsular area of hip known as fracture neck of femur. The fracture neck of femur is well known since the time of Hippocrates (6 B.C.). This fracture commonly encountered in elder population after a trivial fall [1]. However fracture neck of femur in adults younger than age 50 years are uncommon and often the result of highenergy trauma [2,3,4]. They account for only 2-3 % of all femoral neck fractures [2,5]. There are so many classification systems are available in literature to classify fracture neck of femur, one of them is Pauwel's [6] classification which based on angle, that the fracture line of distal fragment makes with the horizontal line. Pauwel's has been postulated that femoral neck fracture with a more vertical fracture line (i.e. a high pauwel's angle) may experience more shear forces and therefore may be

predispose to nonunion or loss of fixation. Treatment of femoral neck fracture varies according to patients age and fracture pattern. Although there is controversy regarding which fixation method is ideal, we performing routinely 6.5 mm cancellouscannulated(CC) screw or dynamic hip screw(DHS) fixation to treat femoral neck fractures in young age group. Osteosynthesis with three 6.5 mm cancellouscannulated screw fixation is a less invasive technique, with less soft tissue stripping [7]. However, early loosening of the screws may occur if the lateral cortex is damaged from osteoporosis. In contrast dynamic hip screw, which is a screw-plate system with fixed angle, can achieve more stable fixation in patients with osteoporosis [8]. However, the disadvantages of DHS technique are larger skin incision and more soft tissue dissection.

Nonunion fracture neck of femur in young adults is a vital problem [4,9,10,11] from practical point of view if

Manuscript received: 14th June 2015
Reviewed: 30th June 2015
Author Corrected: 15th July 2015
Accepted for Publication: 25th July 2015

fracture remains untreated for 3 weeks or more it is designated as a neglected fracture. Femoral neck fractures in young adults are associated with high incidence of femoral head AVN [4,12-17]. The rate of AVN reported in literature ranges from 12-86% in younger patients after femoral neck fractures [3,4,14-22]. This devastating complication may lead to collapse of femoral head and subsequent osteoarthritis.

Because of these reasons, these intracapsular fractures of the neck of femur are an enigma [23,24,25] to orthopaedic surgeons and it is a curse for an individual. Still it remains an “unsolved fracture” as results are far from ideal in modern day’s orthopaedics.

Material and Methods

Forty eight patients were surgically treated in Gajra Raja Medical College and Jaya Arogya Hospital Gwalior from June 2006 to October 2008 for fracture neck of femur were included in study. Patients with age between 10-70 years with isolated close intracapsular fracture neck of femur were included and those patients who had been suffered from other systemic illness, age less than 10 years and more than 70 years were

Results

Patients were divided into two groups, DHS group and CC screw group. 30 patients were belonged to DHS group and 18 patients were from CC screw group. In our study average age was 45 years and patients taken from age 10-70 years. Out of 48 patients 32 were males and 16 were females. Out of 48 patients 26 were injured on right side and 22 were on left side. Out of 30 patients of DHS group 21 were united and 9 were failed to union. Out of 18 patients of 6.5 mm CC screw group 13 were united and 5 were non-united. Age wise distribution of patients with union and nonunion showed that maximum number of patients belonged to 20-50 years of age (see table-1). Post-Reduction Pauwel’s angle Type - I were 14 patients, Type – II were 20 patients and Type – III were noticed in 14 patients.

Table 1: Age wise distribution of patients with union and nonunion

Age Group in years	No. of patients	Union	Nonunion
10-20	n = 5	5 (100%)	0
21-30	n = 11	6 (54.55%)	5 (45.55%)
31-40	n = 12	10 (83.33%)	2 (16.66%)
41-50	n = 11	7 (63.64%)	4 (36.36%)
51-60	n = 7	3 (42.86%)	4 (57.14%)
61-70	n = 2	1 (50%)	1 (50%)
Total	48	34	14

Out of 30 patients of DHS group, 21 united and 9 were failed to union. Out of 18 patients of CC screw group 13 were united and 5 were non-united. All over 34 patients were united and 14 patients were nonunited observed in our study. In our study it has been observed that union rate was decreasing with raising of age (see table 1).

excluded from study. 30 patients were treated with DHS fixation and 18 patients were treated with 6.5 mm CC screw fixation. All surgeries performed under spinal anaesthesia on Watson – Jones fracture table under fluoroscopic control after reduction of fracture by Whitmann [26] or Leadbetter [27] method. Preoperative parental antibiotics were administered 1 hr before surgery [28]. On second postoperative day sitting on bed allowed with quadriceps and ankle pump exercise started. Check X-ray was done with operated limb in 15 degree internal rotation and Post-Reduction Pauwel’s angle was measured and noted. All patients were followed upto 12 months to see clinically and radiological union. Partial weight bear allowed only after the radiological appearance of union which took about 6 to 10 weeks after surgery. Final functional outcome made by using Harris Hip Score system (HHS) [29].

Pauwel’s Classification [6]:

Type I – 0-30 degree

Type II – 30-50 degree

Type III – 50- 70 degree

Table 2: Implant wise distribution of patients with union and nonunion

Implant	No. of Patients	Union	Nonunion
DHS	n = 30	21 (70%)	9 (30%)
6.5 CC Screw	n = 18	13 (72.72%)	5 (27.18%)
Total	48	34	14

It has been concluded in our study that as the Post -Reduction Pauwel's Angle was increasing the Union rate was decreasing from 41.18 % in 21-30 degree to 2.94 % in 60-70 degree(see table –3 and fig.4).

Table 3: Distribution of patients according to Post Reduction Pauwel's angle with union and nonunion.

Pauwel's Angle in Degree	No. of patients	Union	Nonunion
10-20	0	0	0
21-30	14	14 (41.18%)	0
31-40	14	12 (35.29%)	2
41-50	6	4 (11.76%)	2
51-60	9	3 (8.82%)	6
61-70	4	1 (2.94%)	3
71-80	1	0	1
Total	48	N= 34	14

Table 4: Distribution of patients according to post reduction pauwel's angle with used implant wise

Pauwel's Angle in degree	DHS	6.5 mm CC screw
10-20	0	0
21-30	9 (9, 0)	5 (5, 0)
31-40	9 (7, 2)	5 (5, 0)
41-50	4 (3, 1)	2 (1, 1)
51-60	4 (1, 3)	5 (2, 3)
61-70	3 (1, 2)	1 (0, 1)
71-80	1 (0, 1)	0
	30 (21, 9)	18(13, 5)

Final clinical outcome assessed on basis of Harris Hip Score and showed that 81 % were fair to excellent and 19 % with poor results(see table 5).

Table 5: Final clinical outcome

Result	Harris Hip Score	Percentage	No of patients	DHS	CC Screw
Excellent	90-100	18.75	9	6	3
Good	80-90	47.92	23	13	10
Fair	70-79	14.58	7	4	3
Poor	69 or less	18.75	9	7	2

Discussion

German surgeon Friedrich Pauwel (1885-1980)[6] focused on biomechanical factor that influenced bone growth and repair in fracture neck of femur. He divided the force R (the sum of all forces acting upon the hip joint) into a partial force P, consisting solely of the pressure encountered between the head and neck fragments, and a force S, which

represent the force pushing down from above on the femoral head. If P is more than S, a compression force D occur, which produces union. If P is less than S, shear and tension forces supervenes, making bony union improbable. The shearing force is defined as the uninhibited shear force K_s . Thus three types of fracture may be defined:

Type I
Mechanical load produces functional compression force.

Type II
The mechanical load produces shear forces and latent compression.

Type III
The mechanical load Produces uninhibited shear force coupled with tension force (two detrimental forces)

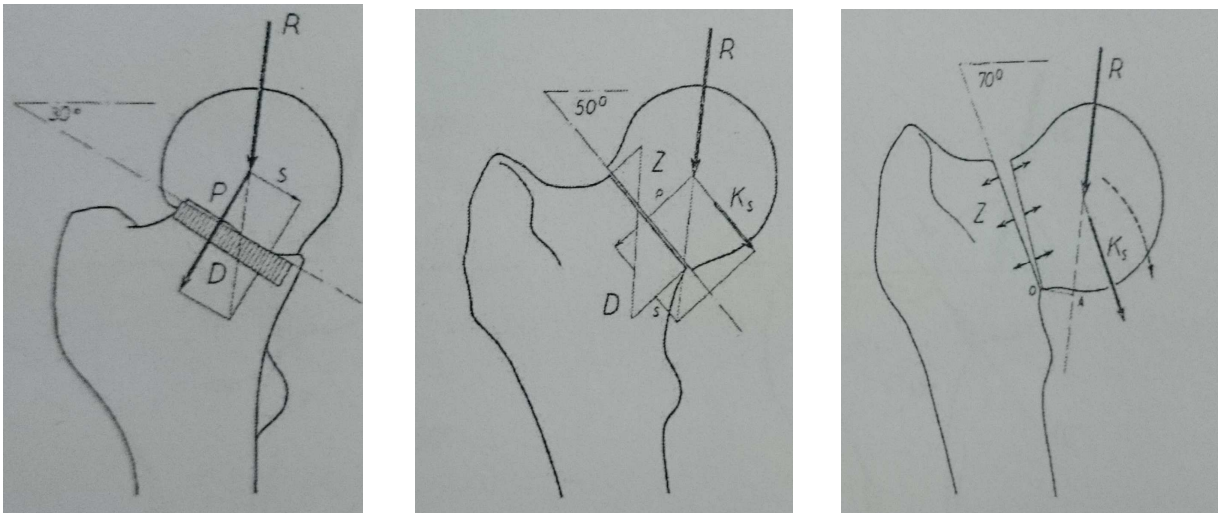


Figure 1: Original illustration by Pauwels 19356: Classification of femoral neck fractures.

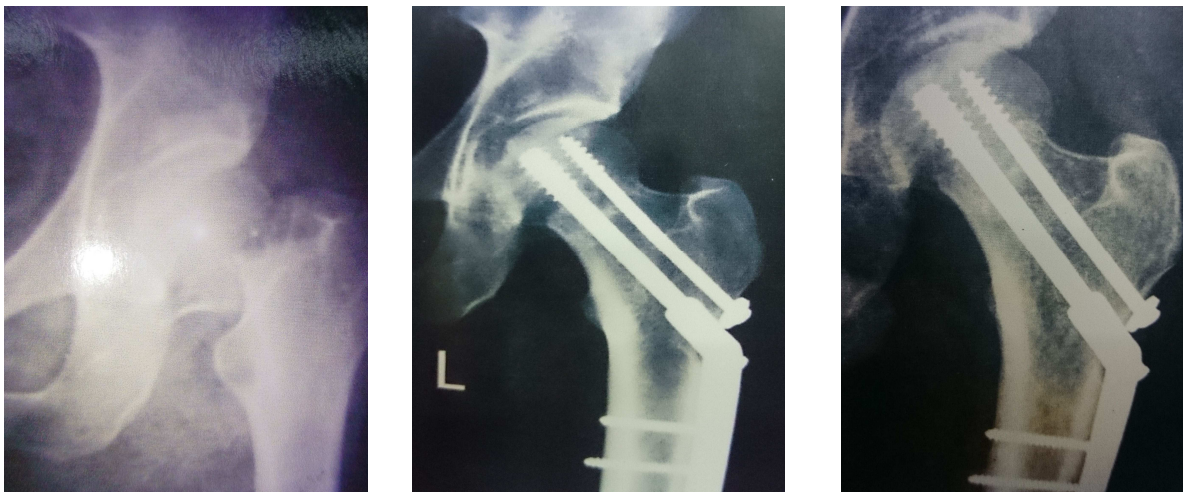

Figure 2 : Pre-op X ray

Immediate Post-op Xray

After 1 Year

Asnis and Sgaglione surgically treated the fracture neck of femur with 6.5 mm CC screw fixation which placed in 141 patients [30]. Husby et al [31] and Selvan [32] favoured the application of the CC screw in a triangular fashion to fix the fracture neck of femur. Krastman et al [33] showed incidence of AVN was 6 % and 2 patients has nonunion in his series.

Hulth A. (1961) found an increased risk of nonunion in pauwel's type III in a series of 42 displaced intracapsular neck fracture treated by internal fixation [34].

Boyd and Salvatore (1964) used the Pauwel's classification but stated that a Pauwel's type – I fracture was impacted, Pauwel's type –II fracture was displaced with a transverse fracture line, and a Pauwel's type –III fracture was displaced with the oblique fracture line [35].

Eklund and Eriksson (1964) stated results were better for Pauwel's Type –I fracture on a series of 53 cases [36]. Frank Liporice et al (2008) evaluated a large consecutive series of high shear angle (> 70 degree) femoral neck fractures to learn more about the outcome, complications and performance of various internal fixation strategies [37]. 37 fractures were treated with CC screws and 25 with a fixed angle device with mean age was 42 years in his series. There was a Nonunion of 7(19%) of the 37 fractures treated with CC screw fixation as compared with 2 (8%) of 25 fractures treated with a fixed angle device. AVN occurred after treatment of 7(11%) of 62 fractures.

A recent study in 2009 by Majernicek M et al [38] found 73.4% union rate in fracture neck of femur fixed with DHS while 26.6% complication though the average age was 21.5 years in the study. In our study it has been 70% union and 30% nonunion if fracture treated with DHS and 72.72% union and 27.18% nonunion if fixed with 6.5 mm CC screw although average age was 45 years.

Although all previous studies described in literature were correlate their results with Pre-Reduction Pauwel's Angle in fracture neck of femur but in our study we correlated results with Post-Reduction Pauwel's Angle. Failure rate were not significantly different, this study documents the challenging nature of this fracture pattern and ideal fixation device remains undefined.

Conclusion

Post Reduction Pauwel's Angle is a good guide to know the stability of fractures and decrease in this angle corrects shearing instability at the fracture site. We had concluded that higher the post reduction pauwel's angle, union rate was decreased. Nonunion and AVN are two most common challenging complications and more difficult to treat as compare to fracture neck of femur itself. With encouraging results from our study, we came to the conclusion that this was another attempt to protest against defeatism to the "unsolved fracture". Initial fracture displacement and disruption of the femoral head blood flow are contributing factors that are out of surgeon's control. However, there are other factors under the surgeon's control that can minimize and prevent these complications one of them may be valgus osteotomy. This study indicates that with vertical fracture line, probably a valgus osteotomy might help in decreasing the incidence of nonunion.

Funding: Nil

Conflict of interest: Nil

Permission from IRB: Yes

Abbreviations:

B.C. : Before Christ

CC :Cannulated Cancellous

DHS : Dynamic Hip Screw

AVN : Avascular Necrosis

HHS: Harris Hip Score

References

1. Christodouliou NA, Dretakin EK. Significance of muscular disturbances in the localization of fracture of the proximal femur. *Clin Orthop Relat Res.* 1984 Jul-Aug;(187):215-7.
2. Robinson CM, Court –Brown CM ,McQueen MM, Christie J. Hip fractures in adult younger than 50 years of age : Epidemiology and Result. *ClinOrthopRelat Res.*1995Mar;(312):238-46. *ClinOrthopRelat Res.* 1995 Mar;(312):238-46.
3. Askin SR, Bryan R. Femoral neck fractures in young adults. *ClinOrthopRelat Res.* 1976 Jan-Feb;(114):259-64.
4. Protzman RR, Burkhalter WE. Femoral neck fractures in young adults. *J Bone Joint Surg Am.* 1976 Jul;58(5):689-95.
5. Zetterberg CH, Elmerson S, Anderson GB. Epidemiology of hip fractures in Gotenberg, Sweden, 1940-1983. *ClinOrthopRelat Res.* 1984 Dec;(191):43-52.

6. Pauwel F. (1935) Der schenkelhalsbruecheinmechanisches problem. Z Orthoplhre Grenzgeb,63, 1-135.
7. Lee YS, Chen SH, Tsuang YH, Huang HL, Lo TY, Huang CR(2008): Internal fixation of undisplaced femoral neck fractures in the elderly: A retrospective comparison of fixation methods. The Journal of Trauma :injury,infection,and critical care : J Trauma 2008 Jan : 64(1): 155-62.
8. Jewell DP, Gheduzzi S, Mitchell MS, Miles AW(2008): Locking plates increases the strength of dynamic hip screw. Injury.2008 Feb;39(2):209-12. Epub 2007 Sep 18.
9. Massic WK. Fracture of the hip .J Bone Joint Surg Am. 1964 Apr;46:658-90..
10. Zolczer L, Kazár G, Manninger J, Nagy E. Fracture of the femoral neck in adolescence. Injury. 1972 Aug;4(1):41-6.
11. Kalra M¹, Anand S. Valgus intertrochanteric osteotomy for neglected femoral neck fractures in young adults. IntOrthop. 2001;25(6):363-6.
12. Dedrick DK, Mackenzie JR, Burney RE. Complication of femoral neck fracture in young adults. J Trauma. 1986 Oct;26(10):932-7.
13. Zetterberg CH, Irstam L, Andersson GB. Femoral neck fractures in young adults. ActaOrthop Scand. 1982 Jun;53(3):427-35.
14. Swiontkowski MF, Winqvist RA, Hansen ST Jr. Fractures of the femoral neck in patients between the ages of twelve and forty nine years. J Bone Joint Surg Am. 1984 Jul;66(6):837-46.
15. Kofoed H. Femoral neck fractures in young adults. Injury. 1982 Sep;14(2):146-50.
16. Shih CH, Wang KC. Femoral neck fractures. ClinOrthopRelat Res. 1991 Oct;(271):195-200.
17. Lee CH, Huang GS, Chao KH, Jean JL. Surgical treatment of displaced stress fracture of the femoral neck in military recruits: A report of 42 cases. Arch Orthop Trauma Surg. 2003 Dec;123(10):527-33. Epub 2003 Sep 2.
18. Visuri T, Vara A, Meurman KO. Displaced stress fractures of the femoral neck in young male adults. A report of twelve operation cases. J Trauma. 1988 Nov;28(11):1562-9.
19. Haidukewych GJ, Rothwell WS, Jacofsky DJ, Torchia ME, Berry DJ. Operative treatment of femoral neck fractures in patients between the ages of fifteen and fifty years. J Bone Joint Surg Am. 2004 Aug;86-A(8):1711-6.
20. Upadhyay A, Jain P, Mishra P, Maini L, Gautam VK, Dhaon BK. Delayed internal fixation of fractures of the neck of the femur in young adults. J Bone Joint Surg Br. 2004 Sep;86(7):1035-40.
21. Tooke SM, Favero KJ. Femoral neck fractures in skeletally mature patients, fifty years old or less. J Bone Joint Surg Am. 1985 Oct;67(8):1255-60.
22. Gautam VK, Anand S, Dhaon BK. Management of displaced femoral neck fractures in young adults (a group at risk) Injury. 1998 Apr;29(3):215-8.
23. Raaymakers EL. Fractures of femoral neck: A review and personal statement. Acta ChirOrthopTraumatolCech. 2006;73(1):45-59.
24. Dickson JA. The unsolved fractures of protest against defeatism. J Bone Joint Surg Am. 1953 Oct;35-A(4):805-22.
25. Grewal KS. Fracture neck of femur. Kini Memorial Oration: Annual Conference of Association of Surgeons of India, Jaipur 1959.
26. Whitmann R: A new treatment for fracture of the femoral neck . Med. Rec.1904;65:441.
27. Leadbetter GW. A treatment of fracture neck of the femur. ClinOrthopRelat Res. 2002 Jun;(399):4-8..
28. Tengre and J. Kjellander ; Antibiotic prophylaxis in operation on trochanteric femoral fractures; Scan J Prim health care Sep 2002 :20(3);188-92.
29. Harris WH. Traumatic arthritis of the hip after dislocation and acetabular fractures: treatment my mold arthroplasty .An end result study using a new method of result evaluation .J Bone Joint Surg Am. 1969 Jun;51(4):737-55.

30. Asnis SE, Sgaglione LW (1994): Intracapsular fractures of the femoral neck. Results of cannulated screw fixation. *J Bone Joint Surg Am* 1994;76(12):1793-803.
31. Husby T, Alho A, Ronningen H. Stability of femoral neck osteosynthesis. Comparison of fixation methods in cadavers. *Acta Orthop Scand*. 1989 Jun;60(3):299-302.
32. Selvan VT, Oakey MJ, Rangen A, Al-Lami MK (2004): Optimum configuration of cannulated hip screws for the fixation of intracapsular hip fractures : a biomechanical study. *Injury*. 2004 Feb;35(2):136-41.
33. Krastman P, van den Bent RP, Krijnen P, Schipper IB. Two cannulated hip screws for femoral neck fractures ; treatment of choice or asking for trouble. *Arch Orthop Trauma Surg*. 2006 Jul;126(5):297-303. Epub 2006 Apr 21.
34. Hulth A. The inclination of the fracture surface and its relation to the result of healing in femoral neck fractures. *Acta Chir Scand*. 1961 May;121:309-14..
35. Boyd HB, Salvatore JE, Acute fractures of the femoral neck: internal fixation or prosthesis? *J Bone Joint Surg Am*. 1964 Jul;46:1066-8.
36. Eklund J. and Eriksson F. Fractures of the femoral neck :with special regard to the treatment and prognosis of stable abduction fractures. *Acta Chir Scand*. 1964 Apr;127:315-37.
37. Frank Liporice, Robert Gaines, Cory Collinger, George J, Haidukewych . Results of internal fixation of pauwel's type -3 vertical femoral neck fractures. *J Bone Joint Surg Am*. 2008 Aug;90(8):1654-9. doi: 10.2106/JBJS.G.01353..
38. Majerníček M, Dungal P, Kolman J, Malkus T, Vaculík J. Osteosynthesis of intracapsular femoral neck fractures by dynamic hip screw fixation. *Acta Chir Orthop Traumatol Cech*. 2009 Aug;76(4):319-25.

.....
How to cite this article?

Ganvir A, Sirsikar A, Gupta S. Outcome analysis of post reduction pauwels angle in fracture neck of femur treated with dynamic hip screw or 6.5 mm cancellous cannulated screw fixation. *Int J Med Res Rev* 2015;3(6):648-654. doi: 10.17511/ijmrr.2015.i6.129.

.....