

A Morphometric study of superior mesenteric artery and its implication in laparoscopic Surgery

¹Mane RM, ²Shinde C

¹Dr. Rekha Maruti Mane, Assistant professor, Department of Anatomy, ²Dr. Charushila Shinde, Assistant Professor, Department of Anatomy, Mahatma Gandhi Mission medical college, Navi Mumbai, Maharashtra, India

Address for Corresponding: Dr. Rekha Maruti Mane, **Email:** dr_rekhamane@yahoo.com

Abstract

Introduction: As the field of intestinal surgery advanced over the recent century, challenge of performing more complex resection and anastomoses highlighted the presence of vascular variants. The current clinical interest of these anatomic finding is to laparoscopic colon surgeon. **Material and method:** The study was conducted on a 50 embalmed human cadavers in the Anatomy dissection hall. We performed detailed dissection to measure length and to note a branching pattern of Superior mesenteric artery and its branches. **Results:** In all 50 cases Superior Mesenteric Artery (SMA) was originated from abdominal aorta, separated from celiac trunk by 0.9cm \pm 0.29. All five branches were seen in all samples with 2% showed additional branches. A common trunk of Right Colic artery (RCA) and Middle Colic artery (MCA) was noted in 42%. The numbers of Jejuno-Ileal branches were 7-13 in number with most common was 9 (26%). Additional branch from jejunal artery to other viscera was present in 4%. Mean length of MCA, RCA and Ileo-colic was 3.23 \pm 1.51, 3.42 \pm 1.17, and 4.57 \pm 0.98 respectively. Pattern of distribution noted was Type A 58%, Type B 32%, Type C 10%. **Conclusion:** A normal pattern of colonic vasculature as accepted by most of medical textbook was not seen in all of the cases. The interest in these anatomical concepts was not simply to Anatomist but also to surgeons while performing a safe and efficient laparoscopic or conventional colon surgery.

Key words: Superior Mesenteric Artery, Right Colic Artery, Middle Colic Artery

Introduction

Surgery has undergone several important changes over last decades. Technologic and molecular advances have fundamentally changed the way diseases are treated. In search of giving patient a best possible outcome new modalities are added or older ones undergoes renewal. Applications of these new management skills require comprehensive anatomical background. Pathological involvement of colon is quite frequent. It ranges from simple benign lesion to fulminate malignant lesion. Certain anatomical facts like pattern of distribution, variant course and branches should be taken into consideration in dealing with them. In carcinoma of colon, Resection (colectomy) is one of the modality of treatment. This entails ligation of the appropriate colic arteries at their origin [1, 2]. Thus arterial supply of the specific segment must be identified in order to offer the patient the best possible "oncologic" operation. Certain operation that require incision of the supposed avascular area of the transverse mesocolon, like retro colic anastomoses (where variant MCA could be injured) also

require an understanding of the some fine points of mesenteric vascular anatomy [3]. The current clinical interest of these anatomic finding is in laparoscopic colonic surgery where inability to palpate these vessels and use of techniques that ligate these mesenteric vessels intracorporeally requires a thorough knowledge of mesenteric anatomy [2,4]. This knowledge of the normal and variant anatomy of the major unpaired arteries originating from the abdominal aorta and their variants is necessary to accomplish a successful, uncomplicated abdominal operation.

Materials and Methods

The study was conducted on 50 embalmed human cadavers in the Anatomy dissection hall of the MGM Medical College and hospital of Navi Mumbai. Cadavers with distorted normal anatomy due to abdominal surgery were excluded. SMA and its branches were exposed by following standard methods of dissection [5, 6]. The anterior abdominal wall of embalmed cadaver was incised by taking two incisions. Skin flaps and muscles of anterior abdominal wall were reflected. Peritoneal cavity was exposed. Greater omentum, small intestine with its

Manuscript received: 4th Mar 2015
Reviewed: 19th Mar 2015
Author Corrected: 5th Apr 2015
Accepted for Publication: 24th Apr 2015

mesentery and large intestine was identified. The transverse colon and greater omentum was turned superiorly over costal margin. The coils of the jejunum and ileum were moved to the left side of the abdomen so that the right side of the mesentery faces anteriorly. Peritoneum on the right side of mesentery was removed to expose the branches of superior mesenteric artery Length of individual branches was measured using measuring tape. Pattern of arrangement and distribution of arteries into type A, B, and C and their numbers were noted. All observations were tabulated and statistically analyzed.

Results

In this study, total 50 embalmed cadavers were dissected. SMA with its branches and its pattern of distribution were studied. In all the 50 cadavers SMA was originated individually from an abdominal aorta as a ventral branch separated from celiac trunk by mean distance of 0.9 cm (0.5-1.4cm).

Branches of SMA given on right side (IPDA, MCA, RCA and Ileocolic artery) were found in all cadavers. Additional branch i.e. Left colic artery was noted from right side in one cadaver.

MCA and RCA may originate as common trunk or as independent branches. Common trunk was noted in 42% (21) cadavers and non Common trunk was seen in remaining sample 58% (29).

Branches of SMA given on left side supplied Jejunum and ileum. In 49 cadavers, it supplied only small intestine with no additional branches to other viscera. In 1 cadaver (2%) Accessory colic artery was seen arising from first jejunal artery. Numbers of Jejuno-Ileal branches were around 7 to 13. Jejuno-Ileal branches were mostly 9 in number as it was noted in 26% (13) cadaver. (Table 1)

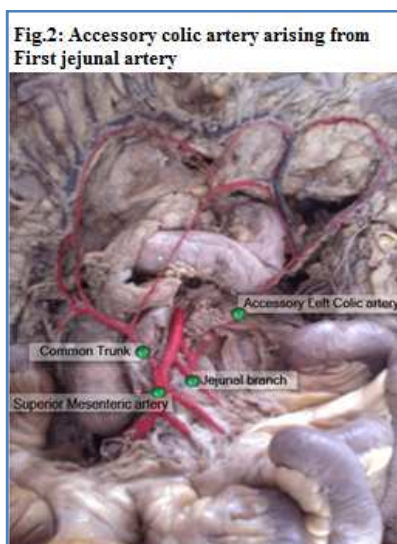
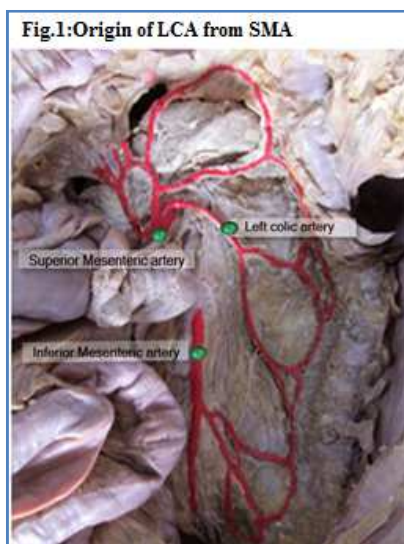


Table 1: Number of Jejuno-Ileal branches

Jejuno-Ileal Branches		
Number	Count	Percentage
7	2	4%
8	5	10%
9	13	26%
10	10	20%
11	7	14%
12	12	24%
13	1	2%
Total	50	100%

Length of branches before its bifurcation was also measured. The mean length of MCA, RCA and ileocolic artery before its bifurcation was 3.2 cm (0.9-7.1cm), 3.4 cm (0.8-5.8cm) and 4.5 cm (3-7.4cm) respectively.

Table 2: Length of Branches

Artery	Mean(cm)	Median(cm)	Mode (cm)	Standard Devaition (cm)	Minimum (cm)	Maximum (cm)
MCA	3.23	2.8	2.2 [#]	1.51	0.9	7.1
RCA	3.42	3.55	2.1 [#]	1.17	0.8	5.8
Ileocolic	4.57	4.4	4.1 [#]	.987	3	7.4

[#] Multiple Mode Exists

Measurements were taken to document distance between branches. Distance between IPDA & MCA, MCA& RCA, RCA & Ileocolic and root of SMA & jejunal was 2.5cm± 0.9, 2.75cm ± 1.05, 2.87cm± 0.8 and 3.34cm ± 0.85 respectively.

Table 3: Distance between Branches

Artery	Mean (cm)	Median (cm)	Mode (cm)	Stardard Deviation (cm)	Minimum (cm)	Maximum(cm)
IPDA & MCA	2.5	2.3	2	0.95	0.8	5.3
MCA & RCA	2.7	2.9	1.7	1.0	0	4.4
RCA & Ileocolic	2.8	2.8	2 [#]	0.8	1	4
Root of SMA & Jejunal	3.3	3.1	3	0.85	1.9	5.1

Pattern of distribution was categorised into different types. Depending upon the number of arterial pedicles it was typed as follows

Type A: Three arterial pedicles. (Fig. 3)

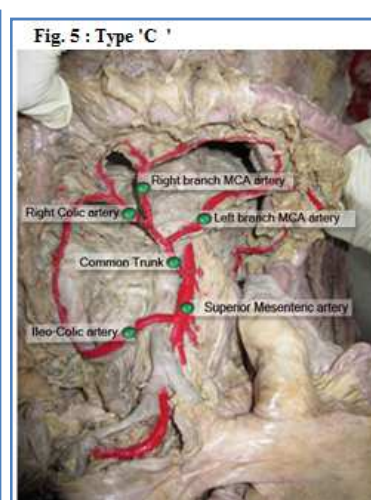
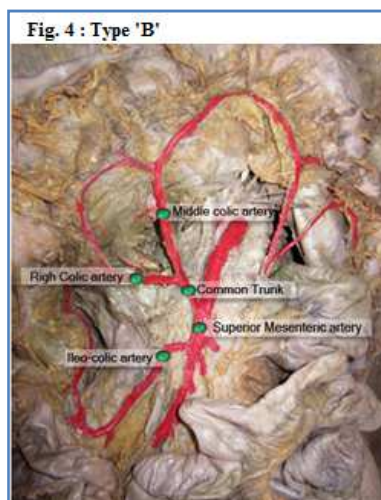
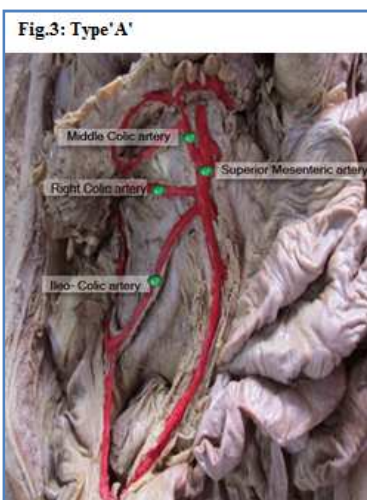
Type B: Two arterial pedicles having a common trunk of MCA and RCA. (Fig.4)

Type C: Two arterial pedicles having a common trunk of MCA and RCA with branches of MCA arise individually. (Fig. 5)

In this study percentage of type A, B, C was 58%, 32%, and 10% respectively.

Table 4: Pattern of Distribution of Superior Mesenteric Artery

Type of Pattern	Count	Percentage (%)
Type A	29	58%
Type B	16	32%
Type C	5	10%



Discussion

The abdominal vessels, especially the celiac trunk (CT) and the superior mesenteric artery (SMA) frequently shows diverse anomalies in their origin and course thus these arteries are studied with great interest. Several anatomic and radiologic descriptions of variation in the origin of the ventral branches of abdominal aorta had been reported in the literature [7]. Until now to our knowledge only celiacomesenteric trunk (CMT) or celiac- bimesenteric trunk had been described. The incidence of celiacomesenteric trunk was reported to be low ranging from 0.4-2.7% [8]. CMT is associated with various other arterial anomalies [9,10,11]. In all our 50 cadavers SMA originates from abdominal aorta 100%.

Topographic study of colonic artery was done in past. George R. studied 94 cadavers in which distance between SMA and celiac trunk was 1.6cm (range 0.5 - 3.1cm) [12]. In our study on 50 cadavers distance was 0.9cm (0.5-1.4cm)

Amongst the three major arteries supplying colon the ileocolic was constant as cited by many authors. In all 50 cadavers, three major arteries were found but only difference existed in its pattern of branching.

The RCA was described as occurring with variable frequency from 38%-78% and the MCA from 44%-87.8% [13,14]. RCA it may arise as a separate branch from the right side of the superior mesenteric artery (35%) or from the ileocolic artery (when it is referred to as an accessory right colic artery 10%), and occasionally it may be absent (less than 5%) [15]. The frequency of MCA arising from the celiac trunk, the hepatic artery or the splenic artery was very few 0.5% and 5% [13, 16]. In our study, two arterial pedicles were in 42% and three arterial trunks were in 52%.

Table 5: Number of Colic Arteries arising from SMA (Literature Review)

Author	Year	Sample	1	2	3	4
Nelson TM [17]	1988	50	0	22%	40%	0
Garcia-Ruiz A[18]	1996	56	0	89.3	10.7	0
Present study	2014	50	---	42%	52%	----

SMA gave branches which supplies jejunum and ileum. Those were 7-13 numbers mostly 9 in numbers (24%).

In the study of Igiri AO et al, 72 Nigerian cadavers were dissected to study the pattern of arrangement and distributions of SMA. Result were categorized into three groups depending on its pattern distributions: Group A (60%) Group B (26.7%) Group C (13.3%). In all the cases the jejunal and ileal arteries were respectively 7-12 and 1-3 in number [19]. According to the Gourley EJ et al., SMA supplies entire small bowel by 12-20 jejunal and ileal branches [20].

As per our study, total jejunal and ileal arteries were 7-13 in numbers. Very few literatures were found on anomalous supply of jejunal branches to other viscera. But in our study, we noted two cases of additional supply to other viscera by jejunal artery i.e. to transverse colon and pancreas.

Kiozumi M et al in his study stated that pancreatic branches may arise from SMA, MCA or the upper jejunal arteries but he didn't mention its frequency. He observed that frequency of accessory colic artery from the SMA which supply transverse colon was 49.2%. This was named CSS (arteria colica sinistra superior) [21].

Accessory colic artery originating from the celiac trunk was reported in few literatures and it was certified as homologues with CSS arising from the celiac trunk.

Table 6: Frequency of Accessory colic artery from SMA in past study

Author	Year	Frequency
Kiozumi M [21]	1990	49.2%
Gourley EJ [20]	2005	10%
Present study	2014	2%

Mean length of IPDA, MCA, RCA and Ileo-colic artery was 2 cm, 2.2 cm, 2.2 cm and 4.1cm respectively Distance between individual branches was noted. Mean distance between root of SMA and IPDA, IPDA and

MCA, MCA and RCA, RCA and Ileo-colic were 2 cm, 1.7 cm, 2 cm and 1.5 cm respectively.

Table 7: Measurements found by other authors

Author	Year	Length of branches		
		MCA	RCA	Ileocolic
Garcia-Ruiz A [18]	1995	3-7 cm	2-7 cm	2-12 cm
Gourley EJ [20]	2005	4 cm	---	---
Present study	2014	2.2cm	2.2cm	4.1cm

Depending upon the number of arterial pedicles and its pattern of branching we had divided our results into three categories: Type A: Three arterial pedicles (58%), Type B: Two arterial pedicles having a common trunk of MCA and RCA (32%), Type C: Two arterial pedicles having a common trunk of MCA and RCA with branches of MCA arise individually (10%).

Type A was most commonly documented pattern of arrangement (58%). In year 2010, the pattern of arrangement and prevalence was studied in the Nigerian population. They had divided population into three groups, Group A: Classical three arterial trunks, Jejuno-Ileal branches were 6-17 in number (60%), Group B: Three arterial trunks with ileocolic gave appendicular artery directly (26.7%) and Group C: Two arterial trunks with RCA from the ileocolic artery (13.3%)[19]. According to McGregor AL, three arterial pedicles were seen in 23.8%. RCA arose from the ileocolic and MCA in 22.7% and 21.5% of cases [22]. In a study conducted by Nelson TM et al it was found that RCA and MCA arose separately from SMA in 34% and 58% of samples respectively. In 40% of sample RCA originate as common trunk. The RCA was a branch of an ileocolic artery in 30% [17].

Conclusion

A normal pattern of colonic vasculature as accepted by most of medical textbook was not seen in all of the cases. Most of the cases showed the variant pattern. Our main endpoint was to emphasize on the current anatomical facts about colonic blood supply. The interest in these anatomical concepts was not simply to Anatomist but also to surgeons while performing a safe and efficient laparoscopic or conventional colon surgery.

Funding: Nil, **Conflict of interest:** None initiated.

Permission from IRB: Yes

References

1. Davis MD, Ballantyne GH. Colorectal cancer. In: ballantyne GH, Leahy PF, Madlin IM, eds. Laproscopic surgery. Philadelphia: WB Saunders; 1994:233-56.
2. Milsom JW,Bohm B, Decanini C, Fazio VW. Laproscopic oncologic proctosigmoidectomy with low colorectal anastomoses in a cadaver model. Surg Endosc. 1994 Sep;8(9):1117-23.
3. Kodner IJ, Fry D, Fleshman JW, Birnbaum EH. Colon, rectum and anus. In: Schwartz SI, Shires GT, Spencer FC. Principles of the surgery. 6th ed. New York: McGraw-Hill, 1994:1191-306.
4. Wexner SD, Johansen OB, Nogueras JJ, Jagelman DG. Laproscopic total abdominal colectomy: a prospective trial. Dis Colon Rectum. 1992;35:651-5.
5. Romanes, G. J. Cunningham's Manual of Practical Anatomy. Thorax and Abdomen. London, Oxford University Press, 2004;2:137
6. Tank PW. The abdomen. In: Grant's dissector.15th edition. Baltimore: Lippincott Williams & Wilkins-Wolters Kluwer Health; 2012;107-11
7. Michels NA, Siddharth PL, Kornblith PL, Parke WW. The variant blood supply to the descending colon, rectosigmoid and rectum based on 400 dissections. Its importance in regional resections: A review of medical literature. Dis Colon Rectum. 1965 Jul-Aug;8:251-78.
8. Tanuma K, Kitazawa M, Itonaga T, Ooishi H, Ishiwara A,Kikkawa F. Four cases with the splenic artery of abnormal origin. Kaibogaku Zasshi.1986 Apr; 61(2):130-7.
9. Higashi N, Sone C. A case of celiaco-mesenteric trunk. Kaibogaku Zasshi. 1987 Oct;62(5):550-6.
10. Inokuchi T, Udatsu K, Tagawa T. A case of the truncus celiacomesenteric in an adult, with special references to the posterior pancreatic artery. Med Bull Fukuoka Univ.1981;8:139-42.

11. Yamaki K, Yoshizuka M, Imayama H, Katsume Y, Momota K, Miyazaki M An anomalous case of truncus celiacomesenteric. *J Kurume Med Assoc.*1983;46:893-901.
12. George R. Topography of the Unpaired Visceral Branches of the Abdominal Aorta. *J Anat.* 1935 Jan;69(Pt 2):196-205.
13. Michels, NA, P. Siddharth, P. L. Kornblith and W.W. Parke: The variant blood supply to the small and large intestines. Its import in regional resections. A new anatomic study based on four hundred dissections with a complete review of the literature. *J Internat Coll Surg.* 1963;39:127-170
14. Sonneland, J, Anson BJ, Beaton LE. Surgical anatomy of the arterial supply to the colon from the superior mesenteric artery based upon a study of 600 specimens. *Surg Gynecol Obstet.* 1958 Apr;106(4):385-98.
15. Standring S, et al, eds. *Gray's Anatomy*, 40th Ed. Spain: Churchill Livingstone, 2008. ch. 66, 67 p.1125-1137
16. Sato Y, Takeuchi R, Kawashima T. et al: An anomalous case of a middle colic artery derived from the splenic artery. *J Kyorin Med Soc* 1984;15:87-92.
17. Nelson TM, Pollak R, Jonasson O, Abcarian H. Anatomic variants of the celiac, superior mesenteric and inferior mesenteric arteries and their clinical relevance. *Clin.Anat.* 1988;1(2):75-91
18. Gracia-Ruiz A, Milsom P, Kornblith PL, et al. Right colic arterial anatomy. *Dis Colon Rectum* 1996;39:906-11.
19. Igiri AO, Ekong MB, Egemba GO, Asuquo RO. The pattern of arrangement and distribution of the superior mesenteric artery in a Nigerian population. *Int. J. Morphol.*2010;28(1):33-36
20. Gourley EJ, Gering SA. The meandering mesenteric artery: a historic review and surgical implications. *Dis Colon Rectum* 2005;48:996-1000.
21. Koizumi M, Horiguchi M. Accessory arteries supplying the human transverse colon. *Acta Anat (Basel).* 1990;137(3):246-51.
22. Decker GAG, du Plessis DJ. Lee McGregor's: *A Synopsis of Surgical Anatomy.*12th ed. Bombay, India: Varghese Publishing House; 1995. p.226-228.

.....

How to cite this article?

Mane RM, Shinde C. A Morphometric study of superior mesenteric artery and its implication in laparoscopic Surgery. *Int J Med Res Rev* 2015;3(4):372-377. doi: 10.17511/ijmrr.2015.i4.070.

.....