

Comparison of Retroperitoneal & Transperitoneal Laparoscopic Nephrectomy in Management of Pyonephrosis in Terms of Conversion to Open Surgery

Belim OB¹, Shah NJ², Patil MV³, Pasi B⁴

¹Dr Osman B. Belim, ²Dr N J Shah, ³Dr Milind V Patil, ⁴Dr Bodhraj Pasi. All affiliated with Department of Surgery, Medical College Baroda, Gujrat, India

Address for Correspondence: Dr Belim Osman, E mail: drbelim@yahoo.co.in

Abstract

Introduction: Since the mid-1990s, there has been an evolution in surgical practice from traditional open approaches to minimally invasive means of treating operative lesions. This study is carried out to study rate & indication of conversion to open surgery in pyonephrosis using retroperitoneal and trans peritoneal laproscopic nephrectomy. **Materials And Methods:** This study was retrospective study done in Department of Urology Civil hospital & B J Medical College Ahmadabad .We performed a retrospective review of a maintained database of 219 consecutive laparoscopic simple nephrectomies done for pyonephrosis between July 2001 to February. 2013.. **Results:** In study transperitoneal route using four ports was used in 165 (75.3%) while retroperitoneal access using three was used in 54(24.6%) patients. In our study total 163 (74.4%) had PCN (percutaneous nephrostomy) in situ, 79.3% in lap transperitoneal group and 59.2% in lap retro peritoneal group. 27(12.3%) patients required conversion to open surgery. Adhesion 13(5.9%) and bleeding 9(4.1%) were the main factors for conversion, while 2 (0.9%) patients required conversion due to bowel injury and limited space in 3(1.3%) patients. Conversion rate was 12.1 % (20/165) for transperitoneal procedures while 12.9 % (7/54) for retroperitoneal approach. Laparoscopic approach requires proper placement of ports for meticulous surgical dissection. Preoperative plain and CECT help in identifying renal hilar anatomy as well as the relationship with the surrounding structures. **Conclusion:** In our study, retroperitoneal laparoscopic nephrectomy has to be considered equal to transperitoneal laproscopic nephrectomy in terms of conversion to open surgery.

Key words: Laparoscopy, Nephrectomy, Pyonephrosis,

Introduction

Laparoscopic simple nephrectomy is often far from “simple” even for the most experienced laparoscopic surgeon because the conditions for which it is performed often result in significant perinephric scarring. Since the mid-1990s, there has been an evolution in surgical practice from traditional open approaches toward minimally invasive means of treating operative lesions. Although these changes have been made possible through advances in video technology and instrumentation design, the primary driver has been an increasingly educated patient population seeking less painful means of treatment. Over a century ago, gynecologic colleagues introduced laparoscopic surgery primarily as a diagnostic tool. Only recently has it become a practical and acceptable alternative to treat complex surgical diseases.

The development of the

Manuscript received: 9th Sept 2014

Reviewed: 29th Sept 2014

Author Corrected: 6th Nov 2014

Accepted for Publication: 13th Nov 2014

laparoscopic pelvic lymphadenectomy for patients with prostate cancer inaugurated the role of laparoscopy in treating urologic lesions (Griffith et al, 1990). In June 1990, Clayman and coworkers at Washington University overcame the barriers to laparoscopic solid organ removal by performing the first laparoscopic nephrectomy [1]. In less than 7 hours, an elderly patient with a 3-cm solid renal mass underwent laparoscopic radical nephrectomy through five trocar sites. This accomplishment represents one of the milestones in minimally invasive surgery because it provided the solution for removing a large solid organ without the need for an incision [1]. Since this report, many institutions have verified the utility of laparoscopic approach to address the diseases of the kidney.

Retroperitoneal laparoscopic nephrectomy was introduced by Gauer et al in 1993[2]. Laparoscopic nephrectomy has proven to be beneficial as compared to

open surgery in terms of lesser post operative pain, a shorter hospital stay and a more rapid return to full activity [2, 3].

Materials and Method

This study was done in department of urology Civil Hospital & B J Medical College Ahmadabad. We performed a retrospective review of a maintained database of 219 consecutive laparoscopic simple nephrectomies done for pyonephrosis between July 2001 to February 2013.

Inclusion Criteria

All patients who went for laparoscopic simple nephrectomy for pyonephrosis

Exclusion Criteria

Laparoscopic simple nephrectomy performed for other than pyonephrosis that include

- Obstructive or reflux nephropathy
- Renal tuberculosis
- Multicystic dysplastic kidney
- Reno vascular hypertension
- Acquired renal cystic disease
- Nephrosclerosis
- Symptomatic patients with autosomal dominant polycystic kidney disease.

Patient Evaluation and Preparation

All the patients were given light diet in the previous evening and polyethylene glycol preparation for bowel

wash out. Informed consent obtained with discussion of possible complications.

Operative Procedure

For laparoscopic nephrectomy, the patient is initially positioned supine for induction of general anesthesia. A bladder catheter and nasogastric tube is placed for decompression of the bladder and stomach prior to insufflation. The subsequent steps and positioning of the patient depends on the approach for the procedure.

Retroperitoneoscopic Nephrectomy

Patient is placed in the lateral flank position with elevation of the kidney bridge. Further, the table may be tilted anteriorly to allow the peritoneum and bowel to fall away from the proposed port site. The primary port is placed using a 1.5-cm incision, 2 cm below and posterior to the tip of the 12th rib in the posterior axillary line, deepened down to the thoracolumbar fascia. A balloon dilator was constructed as described by Gaur [2]. The balloon dilator was used to displace the adjacent fat and peritoneum. A 10mm port was then placed in this opening and used as the camera port. The 2nd and 3rd ports were inserted under direct vision. An automatic insufflator was used to maintain the CO₂ pressure at 14mm Hg. The hilar vessels are dissected first and divided. The ureter is dissected and divided. The kidney is mobilized all round and delivered intact by extending a port or by joining two ports. A 18-F ryles tube drain is left behind in the retroperitoneal space through the 5-mm port site at the discretion of the surgeon.

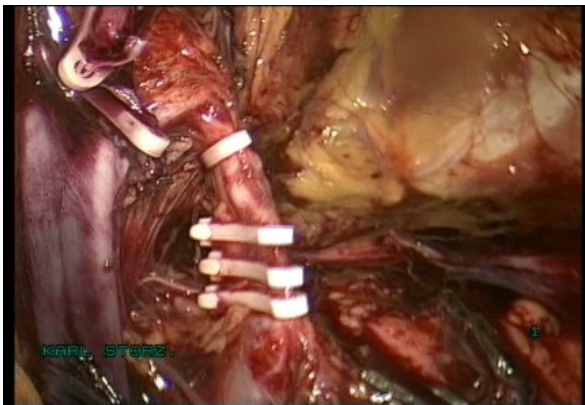


Fig 1: Intra-Operate Photo Hilar Clipping

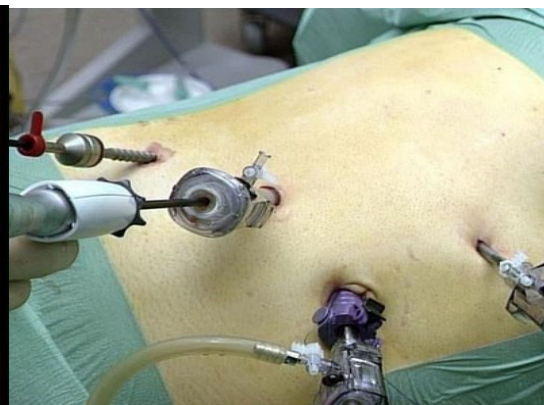

Fig 2: Port Site Laparoscopic Right Simple Nephrectomy

Transperitoneal Laparoscopic Nephrectomy

The patient positioned in a modified lateral decubitus position and the umbilicus is placed over the break in the operating table. An axillary roll is placed and padding used to support the buttocks and flank. The table is rolled toward the surgeon to assist with retraction of the bowel. The abdomen is insufflated using a Veress needle. Trocars are usually inserted near the umbilicus, midway between the iliac crest and umbilicus, just below the costal margin in the midclavicular line, and 4th port at the anterior axillary line midway between the twelfth rib and the iliac crest. In general, 10/12 mm ports are used at the umbilicus and lower quadrant, whereas 5 mm ports are used at the costal and lateral margins. For a left nephrectomy,

Research Article

the white line of Toldt is incised from the level of the iliac vessels to above the spleen including the lienocolic ligament. During a right-sided nephrectomy, the peritoneal incision is carried cephalad, above the hepatic flexure including the right triangular and right anterior coronary ligaments. Medial traction on the colon reveals colorenal attachments that must be divided to complete the colon dissection. Adequate mobilization of the colon reveals the psoas muscle followed by the gonadal vessels and the ureter. The ureter is elevated and followed proximally to the lower pole and hilum of the kidney. The ureter is not divided at this time because it can be used to help elevate the kidney and identify the hilar vessels which are clipped and divided individually after a meticulous hilar dissection. Once the hilar vessels have been divided, the dissection continues posteriorly and superiorly to the upper pole and the adrenal gland is preserved. The ureter is divided and the kidney is removed intact by extending a 10 mm port. The muscle layer of the 10 mm trocar sites is closed with 2-0 vicryl sutures.

Post Operative Care

The nasogastric tube is removed at the completion of the procedure. The patient can begin oral diet as tolerated after the bowel sounds return or next day morning. The foley catheter is removed within 24 hours the patient is ambulating and a drain is removed within 24 hours or when the output is less than 50 ml in 24 hours. The patient is discharged when tolerating a diet.

Results and Observations**Number of Patients**

In our study there were 219 simple nephrectomies of which transperitoneal route was used in 165 (75.3%) while retroperitoneal access was used in 54(24.6%) patients.

Demographics

In our study there was male predominance. Nephrectomy was performed in 120 male patients and 99 female patients, out of 120 males 85 underwent lap transperitoneal nephrectomy and 35 underwent lap retro peritoneal nephrectomy and in females 89, and 19 respectively. In present study right side simple nephrectomy was done in 128 and left side in 91 cases

The mean age at surgery was 55 years (range 3-77 years)

Etiology

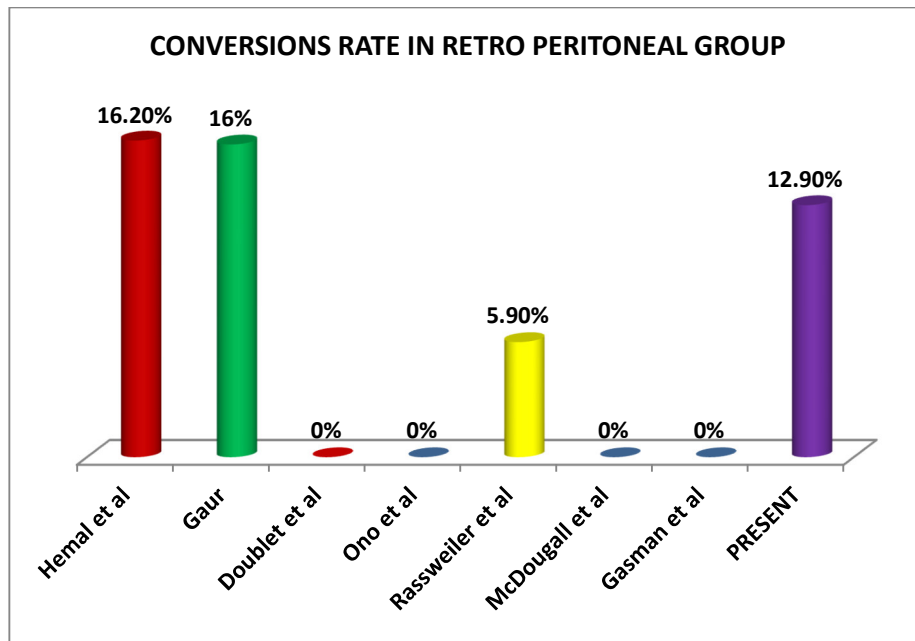
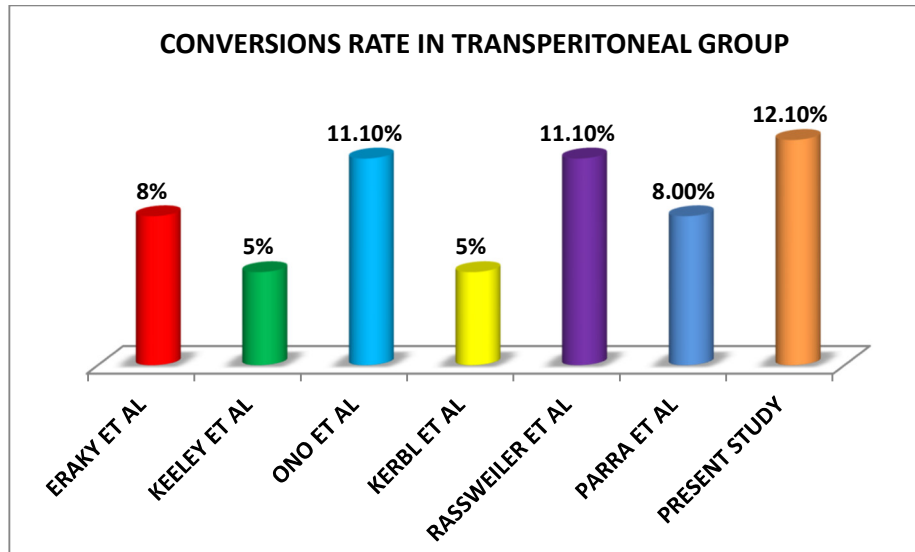
Etiology was Renal stone/Pelviureteric junction stone in 98 (44.75%), Ureteric stone 87 (39.72%), Pelviureteric junction obstruction in 23(10.5%), Ureteric stricture in 9 (4.1%), vesicoureteric reflux in 2 (0.9%).

Etiology				
Renal/ Puj Stone	Uretric Stone	PUJ Obstruction	Uretric Stricture	Vesicoureteric Reflux
98(44.75%)	87(39.72%)	23 (10.5%),	9 (4.1%)	2 (0.9%)

Discussion**Conversion to Open**

The rate of conversion to open surgery in laparoscopic transperitoneal simple nephrectomy is range from (5-11.1 %) and (6-16 %) in laparoscopic retroperitoneal simple nephrectomy in most of the published series. In some series reports higher conversion rate in pyonephrosis up to 80%.

Conversions to open				
S. No	Lap Transperitoneal Group		Lap Retroperitoneal Group	
1	Eraky et al [4]	9 [8%]	Hemal et al [10]	30 (16.2%)
2	Keeley et al [5]	4 (5%)	Gaur [11]	6(16%)
3	Ono et al [6]	3 (11.1%)	Doublet et al [12]	0
4	Kerbl et al [7]	1 (5%)	Ono et al [13]	0
5	Rassweiler et al [8]	2 (11.1%)	Rassweiler et al [14]	-1 (5.9%)
6	Parra et al [9]	1 (8.0%)	Mcdougall et al [15]	0
7	Present study	20(12.1%)	Present study	7(12.9%)

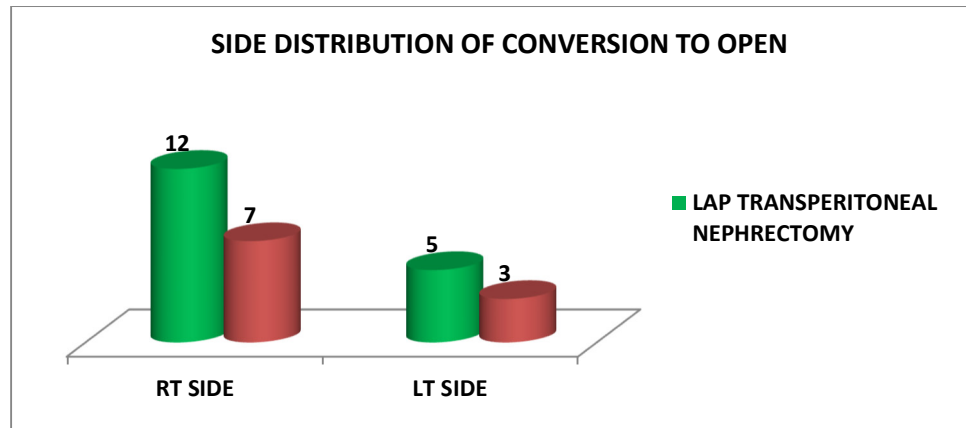


Side Distribution of Conversion to Open

Side Distribution of Coverision	Rt Side	Lt Side
Lap Transperitoneal Nephrectomy	12	7
Lap Retroperitoneal Nephrectomy	7	3

No differences were observed regarding age, body mass index (BMI) or gender distribution between the conversion and no conversion groups and right-sided nephrectomy were associated with higher chances of conversion into an open procedure 8.6% (19/219) as compare to left-sided nephrectomy 3.6% (8/219)

High conversion rate in right nephrectomy are generally associated with difficulty in progressing due to severe perirenal adhesions and fibrosis around short renal vein and inferior vena cava.



As, many simple nephrectomies are far from simple owing to the scarring associated with the pathologic process. Indeed the underlying renal pathology has been shown to have a direct correlation to the incidence of conversion with renal tuberculosis, post-traumatic renal atrophy, infarcted kidneys, and xanthogranulomatous pyelonephritis having an open conversion rate of 89% in one large multi-institutional german study [15]. Total 27 patients required conversion to open surgery (12.3%) with 18 % (18) of these conversions occurring during the first 100 cases only 9 patient required conversion to open in next 129 patients (6.9%). Our rate of conversion is comparable to other series despite that we are performing in difficult pyonephrotic patients

Indication for Conversion to Open

In present study 27(12.3%) patients requiring conversion were having adhesion 13(5.9%) and bleeding 9(4.1%) were the main factors for conversion ,while 2 (0.9%)patients required conversion due to bowel injury and limited space in 3(1.3%) patients. Conversion rate was 12.1% (20/165) for transperitoneal procedures while 12.9 % (7/54) for retroperitoneal approach.

Table: Indication for Conversion to Open

Indication for Conversion to Open	Adhesion	Bleeding	Bowel Injury	Lack of Space
Lap Transperitoneal Nephrectomy	11 (6.6%)	7(4.2%)	2(1.2%)	0
Lap Retroperitoneal Nephrectomy	2(3.7%)	2(3.7%)	0	3(5.5%)

The role of laparoscopic surgery in patients with pyonephrosis has been controversial in earlier laparoscopic series, with higher open conversion and complication rates [16-18]. Reported open conversion rate is 16-33% and complication rate is 20-50% in a contemporary series [19-23]. With increase in advanced laparoscopic experience and skills, LN can be offered in selected patients with acceptable morbidity, decreased blood loss and shorter convalescence [24].

Katz r. e et al reported an overall conversion rate of 5% in a series of 185 laparoscopic nephrectomies with 7% and 15% major and minor Complications rate [25]. Ricardo j et al reported an overall conversion rate of 28% of 50 laparoscopic nephrectomies cases with 9.0% and 12% major and minor Complications rate [26]. Lee et al reported an overall conversion rate of 17% in a series of 31 laparoscopic nephrectomies with 8% and 16% major and minor Complications rate. Zaidi z et al reported an

overall conversion rate of 11.6% in a series of 60 laparoscopic nephrectomies with 3% and 16% major and minor Complications rate [27]. Wayland hsiao et al reported an overall conversion rate of 6.6% in a series of 100 laparoscopic nephrectomies with 20% and 11% major and minor Complications [28]. Hemal ak et al reported an overall conversion rate of 9.8% in a series of 185 laparoscopic nephrectomies with 9.8% and 3.8% major and minor Complications [10]. M. tobias-machado et al reported an overall conversion rate of 11.7% in a series of 17 laparoscopic nephrectomies with 6% and 13% major and minor Complications[29].

Present study- Our data suggest that overall conversion rate of 12.1% in a series of 219 laparoscopic nephrectomies with 6.8 % and 12.7 % major and minor Complications. Our overall rate of conversion and complications was comparable with other series performing lap nephrectomies for nonfunctioning pyonephrotic kidney.

Conclusions

In our study, retroperitoneal laparoscopic nephrectomy has to be considered equal to transperitoneal laparoscopic nephrectomy in terms of conversion to open surgery. In retroperitoneal group lack of space is major concern while in transperitoneal group poor control of bleeding and injury to bowel is main problem. Adhesions are handled better by retroperitoneal laparoscopic surgery.

Funding: Nil

Conflict of interest: Nil

Permission from IRB: Yes

References

1. Clayman RV, Kavoussi LR, Soper Nj, Dierks SM, Meretyk S, Darcy MD, et al. Laparoscopic nephrectomy: initial case report. *J Urol*. 1991 Aug;146(2):278-82.
2. Gaur D D, Agrawal D K, Purohit K C. Retroperitoneal laparoscopic nephrectomy: initial case report. *J Urol*. 1993 Jan;149(1):103-5.
3. Rozenberg H, Bruyere F, Abdelkader T, Husset A, Hamoura H. Transperitoneal laparoscopic nephrectomy. *Prog Urol*. 1999 Dec;9(6):1034-8.
4. Eraky I, el-Kappany HA, Ghoneim MA. Laparoscopic nephrectomy: Mansoura experience with 106 cases. *Br J Urol*. 1995 Mar;75(3):271-5.
5. Keeley FX, Tolley DA. A review of our first 100 cases of laparoscopic nephrectomy: defining risk factors for complications. *Br J Urol*. 1998 Nov;82(5):615-8.
6. Ono Y, Katoh N, Kinukawa T, et al. Laparoscopic nephrectomy, radical nephrectomy and adrenalectomy: Nagoya experience. *J Urol* 1994;152(6 Pt 1):1962-6.
7. Kerbl K, Clayman RV, McDougall EM, et al. Transperitoneal nephrectomy for benign disease of the kidney: a comparison of laparoscopic and open surgical techniques. *Urology*. 1994 May;43(5):607-13.
8. Rassweiler J¹, Frede T, Henkel TO, Stock C, Alken P. Nephrectomy: a comparative study between the transperitoneal and retroperitoneal laparoscopic versus the open approach. *Eur Urol*. 1998;33(5):489-96.
9. Parra RO, Perez MG, Boullier JA, Cummings JM. Comparison between standard flank versus laparoscopic nephrectomy for benign renal disease. *J Urol*. 1995 Apr;153(4):1171-3; discussion 1173-4.
10. Hemal AK¹, Gupta NP, Wadhwa SN, Goel A, Kumar R.. Retroperitoneoscopic nephrectomy and nephroureterectomy for benign nonfunctioning kidneys: a single-center experience. *Urology*. 2001 Apr;57(4):644-9.
11. Gaur DD. Simple nephrectomy: retroperitoneal approach. *J Endourol*. 2000 Dec;14(10):787-90; discussion 791.
12. Doublet JD, Peraldi MN, Monsaint H, et al. Retroperitoneal laparoscopic nephrectomy of native kidneys in renal transplant recipients. *Transplantation*. 1997 Jul 15;64(1):89-91.
13. Ono Y¹, Katoh N, Kinukawa T, Matsuura O, Ohshima S. Laparoscopic nephrectomy via the retroperitoneal approach. *J Urol*. 1996 Sep;156(3):1101-4.
14. Rassweiler J¹, Frede T, Henkel TO, Stock C, Alken P. Nephrectomy: a comparative study between the transperitoneal and retroperitoneal laparoscopic versus the open approach. *Eur Urol*. 1998;33(5):489-96.
15. McDougall EM, Clayman RV, Fadden PT. Retroperitoneoscopy the Washington University Medical School experience. *Urology*. 1994 Apr;43(4):446-52.
16. Keeley FX, Tolley DA. A review of our first 100 cases of laparoscopic nephrectomy defining risk factors for complications. *Br J Urol*. 1998;82(5):615-8.
17. Rassweiler J, Fornara P, Weber M, Janetschek G, Fahlenkamp D, Henkel T, et al. Laparoscopic nephrectomy the experience of the laparoscopy working group of the German Urologic Association. *J Urol*. 1998;160(1):18-21.
18. Bercowsky E, Shalhav AL, Portis A, Elbahnasy AM, McDougall EM, Clayman RV, et al. Is the laparoscopic approach justified in patients with Xanthogranulomatous Pyelonephritis? *Urology*. 1999;54(3):437-42.
19. Kapoor R, Vijjan V, Singh K, Goyal R, Mandhani A, Dubey D, et al. Is laparoscopic nephrectomy the preferred approach in Xanthogranulomatous Pyelonephritis? *Urology*. 2006; 68(5):952-5.
20. Vanderbrink BA, Ost MC, Rastinehad A, Anderson A, Badlani G, Smith A, et al. Laparoscopic versus open radical nephrectomy for Xanthogranulomatous Pyelonephritis: Contemporary outcomes analysis. *J Endourol*. 2007;21:65-70.

Research Article

21. Rosoff J, Raman JD, Del Pizzo JJ. Feasibility of laparoscopic approach in management of Xanthogranulomatous Pyelonephritis. *Urology*. 2006;68(4):711-4.
22. Manohar T, Desai M, Desai M. Laparoscopic nephrectomy for benign and inflammatory condition. *J Endourol*. 2007;21(11):1323-8.
23. Khaira HS, Shah RB, Wolf JS. Laparoscopic and open surgical nephrectomy for Xanthogranulomatous Pyelonephritis. *J Endourol*. 2005;19(7):813-7.
24. Guzzo TJ, Bivalacqua TJ, Pierorazio PM, Varkarakis J, Schaeffer EM, Allaf ME. Xanthogranulomatous Pyelonephritis: Presentation and management in the era of laparoscopy. *BJU Int*. 2009 Nov;104(9):1265-8. doi:10.1111/j.1464-410X.2009.08547.x. Epub 2009 Apr 15..
25. Katz R, Pode D, Golijanin D, Gofrit ON, Shenfeld OZ, Shapiro A, Reissman P. Laparoscopic nephrectomy for infected, obstructed and non-functioning kidneys. *Surg Laparosc Endosc Percutan Tech*. 2004 Dec;14(6):340-3
26. Ricardo J. Duarte, Anuar I. Mitre, José L. Chambô, Marco A. Arap, and Miguel Srougi. *Journal of Endourology*. April 2008, 22(4): 681-686. doi:10.1089/end.2007.0291. Volume: 22 Issue 4: April 17, 2008
27. Zaidi Z, Samad L, Aquil S. Laparoscopic nephrectomy: technique and outcome. *J Pak Med Assoc*. 2007 Jul;57(7):355-9.
28. Wayland Hsiao and John G. Pattaras. *Journal of Endourology*. October 2008;22(10):2285-2290. doi:10.1089/end.2008.9718.

.....

How to cite this article?

Belim OB, Shah NJ, Patil MV, Pasi B. Comparison of Retroperitoneal & Transperitoneal Laparoscopic Nephrectomy in Management of Pyonephrosis in Terms of Conversion to Open Surgery. *Int J Med Res Rev* 2014;2(6):578- 584. doi:10.17511/ijmrr.2014.i06.12

.....