

## Role of grey scale ultrasound and Colour Doppler findings to differentiate ectopic pregnancy from corpus luteum cyst of pregnancy

Kaur N.<sup>1</sup>, Kaur I.<sup>2\*</sup>, Bansal A.<sup>3</sup>, Kaur P.<sup>4</sup>

DOI: <https://doi.org/10.17511/ijmrr.2019.i02.04>

<sup>1</sup> Navkiran Kaur, Professor and HOD, Department of Radiodiagnosis, Rajindra Hospital, Patiala, Punjab, India.

<sup>2\*</sup> Irwinjit Kaur, Junior Resident, Department of Radiodiagnosis, Rajindra Hospital, Patiala, Punjab, India.

<sup>3</sup> Aman Bansal, Junior Resident, Department of Radiodiagnosis, Rajindra Hospital, Patiala, Punjab, India.

<sup>4</sup> Parneet Kaur, Professor, Department of Obstetrics and Gynaecology, Rajindra Hospital, Patiala, Punjab, India.

**Introduction:** Ectopic pregnancy and corpus luteum cyst are two most common differential diagnosis in a patient with UPT positive and no sonographic evidence of intrauterine pregnancy.

**Aim:** To diagnose ectopic pregnancy and to differentiate ectopic pregnancy from corpus luteum cyst of pregnancy on the basis of grey scale ultrasound and colour Doppler findings. **Material and**

**Methods:** This was a hospital based prospective study carried out on a study group of 40 patients with UPT positive and clinical features suggestive of ectopic pregnancy over a period of two years. Grey scale ultrasound and colour Doppler parameters were studied. **Results:** Out of 40 patients, 30 were diagnosed with ectopic pregnancy and 10 with corpus luteum cyst. Ectopic pregnancies had thicker walls as compared to corpus luteum cysts. Most of the ectopic pregnancies had hyperechoic walls as compared to ovaries (80%) and endometrium (60%). Free fluid with echoes was seen in the pelvis in 70% ectopic pregnancies whereas most of the corpus luteum cysts (80%) had no free fluid. Most of the corpus luteum cysts (70%) had clear internal echotexture whereas ectopic pregnancies were mostly lacy or solid. Yolk sac was seen exclusively in ectopic pregnancy (30%). RI <0.4 and RI >0.7 was found to be highly specific for diagnosing ectopic pregnancy. **Conclusion:** Wall thickness of the mass, echogenicity of the wall as compared to ovary and endometrium, internal echotexture of the cystic mass, presence of yolk sac and presence of free fluid with echoes are significant ultrasound parameters which help to differentiate between the two. RI <0.4 and RI >0.7 was found to be highly specific for diagnosing ectopic pregnancy.

**Keywords:** Luteum cyst, Ectopic Pregnancies, Thickness

Corresponding Author	How to Cite this Article	To Browse
Irwinjit Kaur, Junior Resident, Department of Radiodiagnosis, Rajindra Hospital, Patiala, Punjab, India. Email: <a href="mailto:irwinjitkaur@gmail.com">irwinjitkaur@gmail.com</a>	Kaur N, Kaur I, Bansal A, Kaur P. Role of grey scale ultrasound and Colour Doppler findings to differentiate ectopic pregnancy from corpus luteum cyst of pregnancy. Int J Med Res Rev. 2019;7(2):73-79. Available From <a href="https://ijmrr.medresearch.in/index.php/ijmrr/article/view/1039">https://ijmrr.medresearch.in/index.php/ijmrr/article/view/1039</a>	

<b>Manuscript Received</b> 2019-03-10	<b>Review Round 1</b> 2019-03-20	<b>Review Round 2</b> 2019-03-25	<b>Review Round 3</b>	<b>Accepted</b> 2019-03-29
<b>Conflict of Interest</b> No	<b>Funding</b> Nil	<b>Ethical Approval</b> Yes	<b>Plagiarism X-checker</b> 8%	<b>Note</b>



## Introduction

Ectopic pregnancy is the leading cause of direct maternal deaths[1]. The incidence of EP varies with the population, but it has been accounted for 1-2% of all reported pregnancies [2]. The most common site of ectopic pregnancy is the fallopian tube, accounting for nearly 95% cases. In the fallopian tube, the ampulla (70%-80%) is the most common site, followed by isthmus (12%) and fimbria (5%). Other rare subtypes include interstitial pregnancy, cervical pregnancy, ovarian pregnancy, cesarean scar pregnancy and secondary abdominal pregnancy [3]. A clinical dilemma arises in a pregnant patient without any sonographically evident intrauterine pregnancy and a thick walled adnexal cystic structure without definite visualization of the ipsilateral ovary [4]. Corpus luteum cyst of pregnancy is the most common differential diagnosis in a patient with UPT positive and an adnexal mass. The echogenicity of the cyst wall is compared with that of the ovary and the endometrium. Internal echo texture and colour Doppler features of the cyst wall are also considered in an attempt to differentiate the tubal ring of an ectopic pregnancy from that of a corpus luteum [4].

Colour Doppler flow is seen as a ring of peripheral vascularity surrounding the adnexal structure. This is common to both ectopic pregnancy and corpus luteum cyst.

In addition to searching for a vascular ring in the adnexa, measurements of the spectral Doppler pattern can be used to diagnose the presence of an ectopic gestation [5].

## Aims and Objectives

1) To diagnose ectopic pregnancy. 2) To differentiate between ectopic pregnancy and corpus luteum cyst on the basis of Grey Scale Ultrasound features 3) To differentiate between ectopic pregnancy and corpus luteum cyst on the basis of Colour Doppler values.

## Material and Methods

**Place of study:** Department of Radiodiagnosis, Rajindra Hospital, Patiala

**Type of study:** Prospective study

**Sampling method:** 40 patients reporting to ultrasound section with UPT positive and clinical features suggestive of ectopic pregnancy were included in the study

### Inclusion Criteria

- 1) UPT positive
- 2) Clinical features suggestive of ectopic pregnancy (pain, vaginal bleeding, adnexal mass)

### Exclusion Criteria

- 1) UPT negative
- 2) Other adnexal masses on ultrasound

**Examination Technique:** All the patients underwent transabdominal USG with curved transducer having a frequency of 2-5 MHz followed by transvaginal ultrasonography with high frequency transducer having a frequency of 7.5 MHz and Colour Doppler. Gray scale features of the adnexal mass were studied. Mobility of the mass in relation to ovary, wall thickness of the mass, echogenicity of the wall as compared to ovary, echogenicity of the wall as compared to endometrium, internal echotexture of the mass, presence of yolk sac and presence of free fluid with or without echoes were grey scale ultrasound parameters which were studied to differentiate ectopic pregnancy from corpus luteum cyst of pregnancy. On demonstration of a Ring of fire around the adnexal mass, PSV, RI and PI values were observed and used to differentiate between ectopic pregnancy and corpus luteum cyst, and follow up was done.

The patients with features suggestive of ectopic pregnancy were followed up in the Gynecology department and either laparotomy was done or medical management using methotrexate was done. For patients with ultrasound features suggestive of corpus luteum cyst, follow up ultrasounds were done and either intrauterine gestational sac was seen on follow up or spontaneous resolution of cyst was observed following D&C for RPOC.

**Study analysis:** Findings of Gray scale ultrasound and color doppler in differentiating ectopic pregnancy and corpus luteum cyst of pregnancy were compiled and subjected to analysis using appropriate statistical tests. Data was statistically described in terms of mean  $\pm$  standard deviation ( $\pm$ SD), and range, or frequencies (number of cases) and percentages where appropriate. For comparing categorical data, Chi square ( $\chi^2$ ) test was performed. P values less than 0.05 were considered statistically significant. P value  $>0.05$  was considered insignificant. P value  $<0.001$  was considered highly significant.

## Results

In our study group of 40 patients, age distribution ranged from 19-32 years with mean age of 27.05±3.46 years. Grey scale ultrasound parameters of the adnexal mass and colour Doppler values of the peripheral vascularity ring were recorded. Out of 40 patients, 30 patients were diagnosed with ectopic pregnancy and 10 patients were diagnosed with corpus luteum cyst.

**Mobility of mass with respect to ovary:** 27 (90%) ectopic pregnancy masses moved separately from the ovary and 3 (10%) ectopic pregnancy masses did not move separately from the ovary when pressure with transducer was applied. 9 (90%) corpus luteum cysts did not move separately from the ovary and 1 (10%) corpus luteum cyst moved separately from the ovary. These results were statistically highly significant (P<0.001).

**Wall thickness of the mass:** In our study mean wall thickness of ectopic pregnancies was 6.09±1.85 mm and ranged from 3-10 mm. Mean wall thickness of corpus luteum cysts was 3.73±1.29 mm and ranged from 2-6 mm. This difference in mean wall thickness was statistically highly significant (P<0.001).

**Echogenicity of wall as compared to ovary:** Most of the ectopic pregnancies (80%) had hyperechoic walls as compared to ovaries whereas most of the corpus luteum cysts (50%) had hypoechoic walls as compared to ovaries. These results were statistically highly significant (P<0.001)

**Echogenicity of wall as compared to endometrium:** Most of the ectopic pregnancies (60%) had hyperechoic walls as compared to endometrium whereas most of the corpus luteum cysts (90%) had hypoechoic walls as compared to endometrium. These results were statistically highly significant. (P<0.001)

**Table-1: Echogenicity of wall as compared to ovary and endometrium.**

	Echogenicity of wall as compared to ovary				Echogenicity of wall as compared to endometrium			
	Hyperechoic	Isoechoic	Hypoechoic	Total	Hyperechoic	Isoechoic	Hypoechoic	Total
Ectopic Pregnancy (n=30)	24 (80%)	2 (6.67%)	4 (13.33%)	30	18 (60%)	6 (20%)	6 (20%)	30
Corpus Luteum Cyst (n=10)	1 (10%)	4 (40%)	5 (50%)	10	0	1 (10%)	9 (90%)	10

**Internal echo texture of the mass:** In our study, 13 (43.3%) ectopic pregnancies had clear internal echotexture, 6 (20%) had lacy echotexture and 11 (36.6%) were solid.

7 (70%) corpus luteum cysts had clear internal echotexture, 3 (30%) had lacy internal echotexture and none of the corpus luteum cysts was solid. These results were statistically significant (P<0.05).

**Table-2: Internal echo texture of the mass**

Internal Echotexture	Ectopic Pregnancy		Corpus Luteum Cyst	
	Patients	%age	Patients	%age
Clear	13	43.33%	7	70%
Lacy	6	20%	3	30%
Solid	11	36.67%	0	0%
Total	30	100%	10	100%

**Presence of yolk sac in the mass:** In our study, yolk sac was present in 9/30 (30%) ectopic pregnancies. Yolk sac was present in none of the corpus luteum cysts. These results were statistically significant. (P<0.05)

**Free fluid with or without echoes:** Free fluid with echoes was seen in the pelvis in 70% ectopic pregnancies whereas most of the corpus luteum cysts (80%) had no free fluid. These results were statistically highly significant. (P<0.001)

**Table-3: Free fluid with or without echoes**

Free Fluid	Ectopic Pregnancy		Corpus Luteum Cyst	
	Patients	%age	Patients	%age
No Free Fluid	4	13.33%	8	80%
Free Fluid without Echoes	5	16.67%	2	20%
Free Fluid with Echoes	21	70%	0	0%
Total	30	100%	10	100%

**Peak Systolic Velocity of the peripheral vascularity ring:** In our study, the mean PSV of peripheral vascularity ring of ectopic pregnancy was 26.45±18.27 cm/s and ranged from 7-86.5 cm/s. The mean PSV of peripheral vascularity of corpus luteum cyst was 18.93±6.94 cm/s and ranged from 8.6-29.5 cm/s. This difference in mean PSV was not statistically significant.

**Pulsatility index of the peripheral vascularity ring:** In our study, the mean PI of the peripheral vascularity of ectopic pregnancy was  $0.95 \pm 0.50$  and ranged from 0.4 to 1.8. The mean PI of the peripheral vascularity of corpus luteum cyst was  $0.72 \pm 0.27$  and ranged from 0.4 to 1.3. The difference in mean PI was statistically insignificant.

**Table-4: Mean PSV and mean PI of the peripheral vascularity ring.**

Groups	Mean PSV (cm/sec)	Mean PI
Ectopic Pregnancy	26.45±18.27	0.95±0.50
Corpus luteum Cyst	18.93±6.94	0.72±0.27

**Resistive index of the peripheral vascularity ring:** In our study, the RI of peripheral vascularity was  $<0.4$  in 6 (20%) ectopic pregnancies and in none of the corpus luteum cysts. RI ranged from 0.4 to 0.7 in 14(46.6%) ectopic pregnancies and 9 (90%) corpus luteum cysts. RI was  $>0.7$  in 10 (33%) ectopic pregnancies and 1(10%) corpus luteum cyst. The mean RI of ectopic pregnancies was  $0.51 \pm 0.19$  and of corpus luteum cysts was  $0.54 \pm 0.08$ . The difference in mean RI was statistically insignificant, however RI  $<0.4$  was found to be 100% specific for diagnosing ectopic pregnancy and RI  $>0.7$  was found to be 90% specific for diagnosing ectopic pregnancy.

**Table-5: RI of the peripheral vascularity ring.**

RI	Ectopic Pregnancy		Corpus Luteum Cyst	
	Patients	Percentage	Patients	Percentage
Low RI ( $<0.4$ )	6	20%	0	0%
Intermediate RI (0.4-0.7)	14	46.67%	9	90%
High RI ( $>0.7$ )	10	33.33%	1	10%
Total	30	100%	10	100%

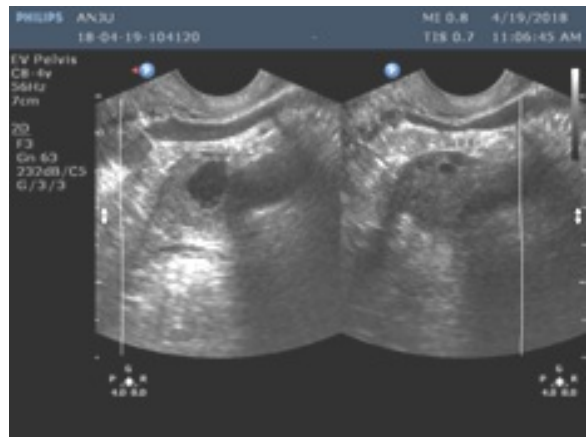


Fig-2

**Figure-1: Hyperechoic Wall of Ectopic pregnancy as Compared to Endometrium**

**Figure-2: Hyperechoic wall of the Ectopic pregnancy as Compared to Ovary**

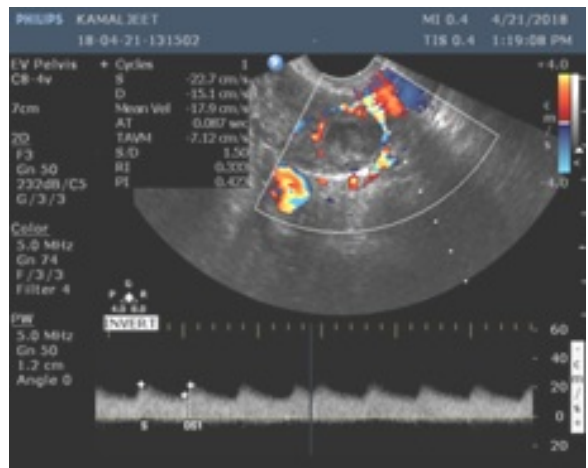


Fig-3

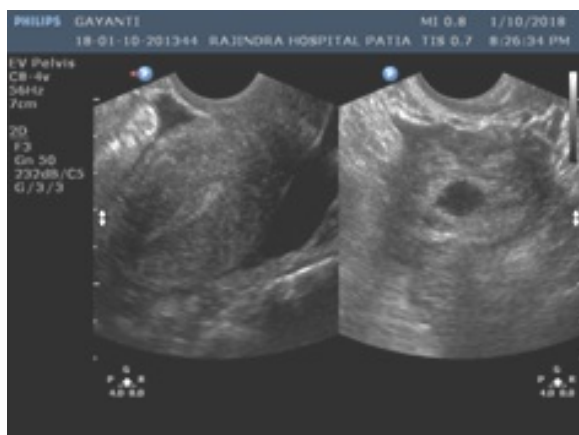

Fig-1

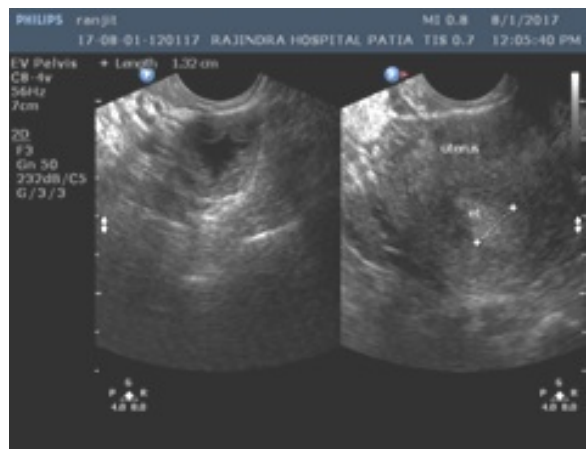

Fig-4

**Figure-3: Colour Doppler of ectopic pregnancy****Figure-4: Hypoechoic Wall of the Corpus luteum cyst as Compared to Endometrium****Discussion**

An adnexal mass that is separate from the ovary is the most common finding of a tubal pregnancy and is seen on ultrasound images in up to 89%–100% of patients. The tubal ring sign is the second most common sign of a tubal pregnancy. In a patient with no identifiable intrauterine pregnancy, it becomes extremely important to differentiate ectopic pregnancy from corpus luteum cyst of pregnancy. Our study aimed to do so by analyzing the grey scale and ColourDoppler parameters.

In our study 27(90%) ectopic pregnancy masses moved separately from the ovary and only 1(10%) corpus luteum cyst moved separately from the ovary. Blaivas et al[6] reported mass separation from the ovary in 93% of ectopic pregnancy cases. Rottem et al [7] also reported similar findings.

In our study mean wall thickness of ectopic pregnancies was  $6.09 \pm 1.85$  mm and ranged from 3–10 mm. Mean wall thickness of corpus luteum cysts was  $3.73 \pm 1.29$  mm and ranged from 2–6 mm. Algazzar et al[8] reported that mean wall thickness in ectopic pregnancy was 7.1 mm compared to 2.6 mm in corpus luteum cysts.

Most of the ectopic pregnancies (80%) had hyperechoic walls as compared to ovaries whereas most of the corpus luteum cysts (50%) had hypoechoic walls as compared to ovaries. Frates et al[9]. (2001) reported that the wall of the tubal ring was more echogenic than the ovary in 88% of ectopic pregnancy patients whereas wall of the corpus luteum cyst was more echogenic in only 7% patients.

Stein et al[4] concluded that 5% ectopic pregnancies had hypoechoic walls as compared to ovaries, 19% had isoechoic walls and 76% had hyperechoic walls as compared to ovaries. About 16% corpus luteum cysts had hypoechoic walls, 50% had isoechoic walls and 34% had hyperechoic walls as compared to ovaries.

Most of the ectopic pregnancies (60%) had hyperechoic walls as compared to endometrium whereas most of the corpus luteum cysts (90%) had hypoechoic walls as compared to endometrium.

Stein et al [4] and Algazzar et al [8] also reported similar findings in which most of the ectopic pregnancies had hyperechoic walls and most of the corpus luteum cysts had hypoechoic walls as compared to endometrium.

In our study, 13 (43.3%) ectopic pregnancies had clear internal echotexture, 6 (20%) had lacy echotexture and 11 (36.6%) were solid. 7(70%) corpus luteum cysts had clear internal echotexture, 3 (30%) had lacy internal echotexture and none of the corpus luteum cysts was solid. Algazzar et al[8] reported that 35.3% ectopic pregnancies had clear internal echotexture, 17.6% had lacy echotexture and 50% were solid whereas 61.5% corpus luteum cysts had clear internal echotexture. Frates et al[10] reported nonspecific mass in 54% ectopic pregnancies.

In our study, yolk sac was present exclusively in ectopic pregnancies (30%). Stein et al[4](2004), Frates and Laing [11] and Frates et al[10] reported presence of yolk sac in 37%, 2.3% and 8.3% ectopic pregnancies respectively.

Free fluid with echoes was seen in the pelvis in 70% ectopic pregnancies whereas most of the corpus luteum cysts (80%) had no free fluid. Stein et al[4] reported that free fluid with echoes was seen in 65% ectopic pregnancies and in only 5% corpus luteum cysts whereas 74% corpus luteum cysts had no free fluid. Chen et al[12] and Fauconnier et al[13] also reported that free fluid with echoes was seen in most of the ectopic pregnancies.

In our study, the mean PSV of peripheral vascularity ring of ectopic pregnancy was  $26.45 \pm 18.27$  cm/s and ranged from 7–86.5 cm/s.

The mean PSV of peripheral vascularity of corpus luteum cyst was  $18.93 \pm 6.94$  cm/s and ranged from 8.6–29.5 cm/s. Atri[5] reported that the mean peak systolic velocity of the ectopic pregnancies was 35.4 cm/s compared with 28.4 cm/s in corpus luteum cysts, with no significant statistical difference ( $P = .1$ ). In our study, the mean PI of the peripheral vascularity of ectopic pregnancy was  $0.95 \pm 0.50$  and ranged from 0.4 to 1.8.

The mean PI of the peripheral vascularity of corpus luteum cyst was  $0.72 \pm 0.27$  and ranged from 0.4 to 1.3. Fukami et al[14](2005) concluded that the mean PI of peripheral vascularity of ectopic pregnancies was  $0.82 \pm 0.31$  and Salim et al[15] (1994) reported that PI of the peripheral vascularity of corpus luteum cysts was  $0.636 \pm 0.09$ .

In our study RI <0.4 was found to be 100% specific for diagnosing ectopic pregnancy and RI >0.7 was found to be 90% specific for diagnosing ectopic pregnancy. Algazzar et al[8] concluded that RI of less than 0.4 had a specificity of 100% for diagnosing EP, and RI of more than 0.7 had a specificity of 96.4% for diagnosis of EP. Atri [5] (2003) reported that RI greater than 0.7 had a specificity of 100% and a positive predictive value of 100% for diagnosing ectopic pregnancy and RI of less than 0.39 had a specificity of 100% for diagnosing ectopic pregnancy. Kurjak et al[16] proposed a cutoff value of 0.40 or less as a diagnostic index for suspected trophoblast in the adnexa.

## Conclusion

Ectopic pregnancy and corpus luteum cyst are two most common differential diagnosis of an adnexal mass in a patient with positive UPT and no sonographically evident intrauterine pregnancy. Mobility of the mass in relation to ovary, wall thickness of the mass, echogenicity of the wall as compared to ovary, echogenicity of the wall as compared to endometrium, internal echotexture of the cystic mass, presence of yolk sac and presence of free fluid with echoes are significant grey scale ultrasound parameters which help to differentiate ectopic pregnancy from corpus luteum cyst of pregnancy.

On color doppler, difference in PSV and PI values are not of much significance in differentiating the two but RI <0.4 was found to be 100% specific for diagnosing ectopic pregnancy and RI >0.7 was found to be 90% specific for diagnosing ectopic pregnancy.

## What this study adds to existing knowledge

Since ectopic pregnancy and corpus luteum cyst of pregnancy are two commonly confused entities clinically as well as on ultrasound, the addition of colour Doppler to grey scale helps to effectively distinguish between the two.

## Reference

01. Schneider J, Berger CJ, Cattell C. Maternal mortality due to ectopic pregnancy- A review of 102 deaths. *Obstet Gynecol.* 1977 May;49(5)557-61. [Crossref]

02. Moini A, Hosseini R, Jahangiri N, et al. Risk factors for ectopic pregnancy- A case-control study. *J Res Med Sci.* 2014 Sep;19(9)844-9. [Crossref]
03. Chanana C, Gupta N, Bansal I, Hooda K, Sharma P, Gupta M et al. Different Sonographic Faces of Ectopic Pregnancy. *J Clin Imaging Sci.* 2017;7;6. [Crossref]
04. Stein MW, Ricci ZJ, Novak L, et al. Sonographic comparison of the tubal ring of ectopic pregnancy with the corpus luteum. *J Ultrasound Med.* 2004 Jan;23(1)57-62. [Crossref]
05. Atri M. Ectopic pregnancy versus corpus luteum cyst revisited- best Doppler predictors. *J Ultrasound Med.* 2003 Nov;22(11)1181-4. [Crossref]
06. Blaivas M, Lyon M. Reliability of adnexal mass mobility in distinguishing possible ectopic pregnancy from corpus luteum cysts. *J Ultrasound Med.* 2005 May;24(5)599-603. [Crossref]
07. Rottem S, Thaler I, Levron J, et al. Criteria for transvaginal sonographic diagnosis of ectopic pregnancy. *J Clin Ultrasound.* 1990 May;18(4)274-9. [Crossref]
08. Algazzar HY, Ghandour AM, Aboueldahab AF, Mohamed AH. Tubal ring sign of ectopic pregnancy versus corpus luteum cyst- best sonographic and color duplex predictors. *The Egyptian J Radiology and Nuclear Med.* 2005;1-7. [Crossref]
09. Frates MC, Visweswaran A, Laing FC. Comparison of tubal ring and corpus luteum echogenicities- a useful differentiating characteristic. *J Ultrasound Med.* 2001 Jan;20(1)27-31. [Crossref]
10. Frates MC, Doubilet PM, Peters HE, et al. Adnexal sonographic findings in ectopic pregnancy and their correlation with tubal rupture and human chorionic gonadotropin levels. *J Ultrasound Med.* 2014 Apr;33(4)697-703. doi: 10.7863/ultra.33.4.697 [Crossref]

11. Frates MC, Laing FC. Sonographic evaluation of ectopic pregnancy- an update. *AJR Am J Roentgenol.* 1995 Aug;165(2)251-9. [Crossref]
12. Chen PC, Sickler GK, Dubinsky TJ, et al. Sonographic detection of echogenic fluid and correlation with culdocentesis in the evaluation of ectopic pregnancy. *AJR Am J Roentgenol.* 1998 May;170(5)1299-302. DOI: 10.2214/ajr.170.5.9574606 [Crossref]
13. Fauconnier A, Mabrouk A, Salomon LJ, et al. Ultrasound assessment of haemoperitoneum in ectopic pregnancy- derivation of a prediction model. *World J Emerg Surg.* 2007 Sep 7;2;23. DOI: 10.1186/1749-7922-2-23 [Crossref]
14. Fukami T, Emoto M, Tamura R, et al. Sonographic findings of transvaginal color Doppler ultrasound in ectopic pregnancy. *J Med Ultrason (2001).* 2006 Mar;33(1)37-42. doi: 10.1007/s10396-005-0064-9 [Crossref]
15. alim A, Zalud I, Farmakides G, et al. Corpus luteum blood flow in normal and abnormal early pregnancy- evaluation with transvaginal color and pulsed Doppler sonography. *J Ultrasound Med.* 1994 Dec;13(12)971-5. [Crossref]
16. Kurjak A, Zalud I, Schulman H. Ectopic pregnancy- transvaginal color Doppler of trophoblastic flow in questionable adnexa. *J Ultrasound Med.* 1991 Dec;10(12)685-9. [Crossref]